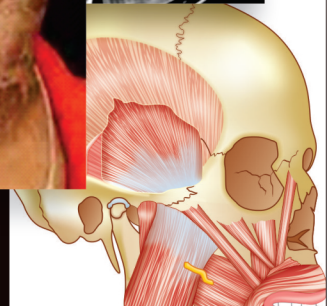
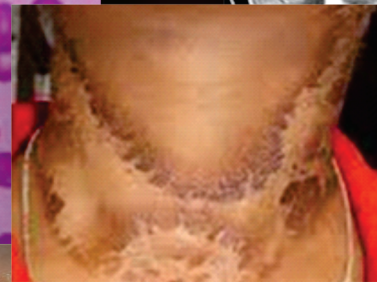
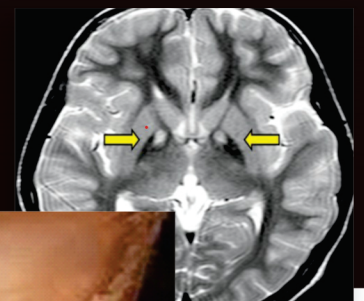
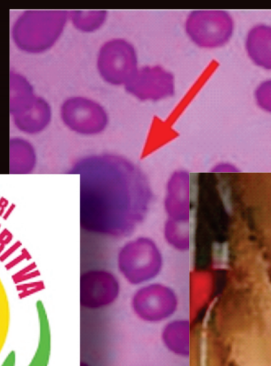
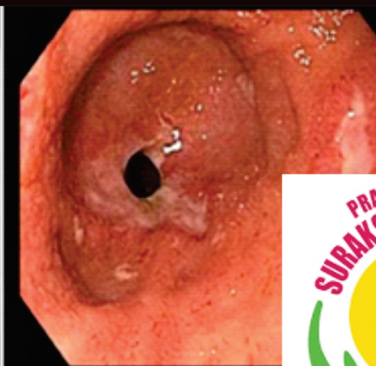
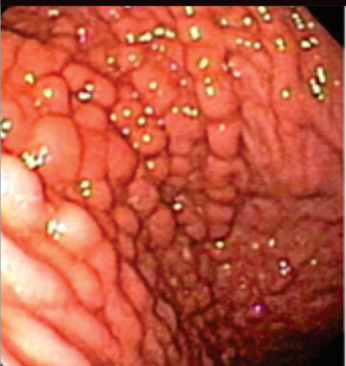First ever book conceptualized on Visual understanding of clinical subjects by
Images • Illustrations • Tables • Flowcharts



ONE Touch Picture Recap

For NEET/NEXT/FMGE/INI-CET



Special Features

- Extensive coverage of 12 Clinical and Short subjects
- 1600+ Clinical Images/Illustrations
- 100+ Clinical scores/stages/classifications/grades
- Important instruments of all clinical subjects
- Important Fundoscopic/Immunofluorescence/Histopathologic findings



CBS Publishers & Distributors Pvt. Ltd.

Sudhir Kumar Singh

ONE Touch



Picture Recap

For NEET/NEXT/FMGE/INI-CET



Sudhir Kumar Singh

MBBS, MCh (JR-Neurosurgery)

All India Institute of Medical Sciences (AIIMS)

New Delhi

CBSPD

Dedicated to Education



CBS Publishers & Distributors Pvt Ltd

- New Delhi • Bengaluru • Chennai • Kochi • Kolkata • Lucknow • Mumbai
- Hyderabad • Jharkhand • Nagpur • Patna • Pune • Uttarakhand

Preface

Dear Readers,

It is with great pleasure and excitement, I introduce to you **One Touch Picture Recap**, a unique and invaluable resource tailored specifically for NEET PG, AFMG, and INI-CET aspirants. This book is the culmination of a vision to transform the way medical students approach their clinical subjects by harnessing the power of visual learning.

In the world of medical education, where time is the essence, we often find ourselves grappling with the challenge of efficiently revising complex clinical topics. **One Touch Picture Recap** has been meticulously crafted to address this very challenge. By condensing the most critical information into a visual format, this book aims to enhance your retention and expedite your revision process.

The distinguishing features of this book are designed with your success in mind. The inclusion of important scores, staging, and grading systems in one place simplifies the often confusing landscape of clinical subjects. Additionally, we have organized previous year topics in a systematic manner, providing you with a comprehensive and structured approach to exam preparation.

The book, offers a range of special features:

- **Extensive Image Database:** It includes an impressive collection of 1600+ images, enriching your understanding and retention of crucial medical concepts.
- **Comprehensive Topic Coverage:** All significant previous year topics are systematically organized within the book, streamlining your study process and ensuring that essential knowledge is readily accessible.
- **Effective Pictorial Illustrations:** The book employs high-quality pictorial illustrations to simplify the intricate medical subjects, aiding in better comprehension and recall.
- **Centralized Clinical Information:** **One Touch Picture Recap** consolidates essential scores, classifications, grades, and stages for surgery, medicine, pediatrics, making it a valuable reference for key clinical information. These features collectively make **One Touch Picture Recap** an invaluable resource for NEET PG aspirants, offering a visually engaging, organized, and comprehensive study tool.

Within the pages of my book, I have poured my heart and soul into creating a beautiful and informative content that I hope will inspire and enlighten you on your path.

Whether you are embarking on your NEET PG journey, aiming for AFMG, or setting your sights on INI-CET, **One Touch Picture Recap** is your trusted companion. Our goal is to empower you with a tool that not only simplifies the complexities of clinical subjects but also instills confidence in your ability to conquer your exams.

I would like to express my gratitude to all those who have contributed to the creation of this book, as well as to you, the aspiring medical professionals, for entrusting us with your educational journey.

I invite you to dive headfirst into this literary voyage, allowing the words to envelop your senses, invoking emotions and evoking images. I hope this book serves as a valuable asset in your pursuit of excellence.

Wishing you all success and a rewarding learning experience with **One Touch Picture Recap**.

Warm regards
Sudhir Kumar Singh

Contents

Preface	v
1. MEDICINE 100+ Images/Illustrations Covered	1-48
• Breathing Patterns	3
• Flow Volume Loop Pattern in Respiratory Disorders	5
• Abnormal JVP Waveforms	8
• Clinical Signs	10
• Electroencephalogram or EEG	14
• ECG Tracings	18
2. SURGERY 250+ Images/Illustrations Covered	49-142
• Triage Categories	51
• Surgical Blades	52
• Types of Needle	53
• Suture Types	53
• Types of Knot	55
• Types of Cautery	56
• Types of Flap	57
• Bags in Surgery	60
• Tubes in Surgery	62
• Drains in Surgery	64
• Breast	66
• Clinical Tests in Thyroid	70
• Premalignant Lesions of Oral Cavity	72
• Barium Studies	73
• Radiological Findings	74
• Clinical Signs	83
• Gallstone and Gallbladder Appearance	88
• Staging/Score/Grade/Classification in Surgery	89
• Intravenous Pyelogram/Intravenous Urogram Findings	111
• Crystal Found in Nephrolithiasis	113
• Clinical Tests in Thoracic Outlet Syndrome	114
• Burn-Chart	115
• Surgical Procedure	117
• Raynaud's Disease	132
• Surgical Instrument	133
3. PEDIATRICS 150+ Images/Illustrations Covered	143-192
• Mile Stone Development	145
• Assessment of Physical Growth	149

• Normal Newborn Conditions	152
• Neonatal Reflexes.....	153
• Genetic Disorder	157
• Marasmus and Kwashiorkor.....	162
• Head Swellings in a Newborn.....	164
• Congenital Defect	166
• Clinical Diagnostic Clue	169
• Score/Stage/Rule in Pediatrics.....	174
• Procedure	179
• Pediatric Radiology	180
• Important Instrument	189
4. OBSTETRICS AND GYNECOLOGY 150+ Images/Illustrations Covered	193-241
• Abnormalities in Placenta	195
• Types of Normal Pelvis	198
• Types of Contracted Pelvis.....	199
• Normal Ultrasound Morphology of the Uterus in Fertile Women.....	200
• Stage-Wise Ultrasound in Pregnancy	202
• Signs in Pregnancy	204
• Gestational Age and Fundal Height.....	206
• Multiple Pregnancies	207
• Placenta Accreta vs Placenta Increta vs Placenta Percreta.....	208
• Types of Placenta Previa.....	208
• Breech Presentation	209
• Types of Maneuver	210
• Classification of Forceps Deliveries.....	215
• Ultrasound Findings in Abnormal Pregnancy	216
• Infectious Vulvovaginitis.....	218
• Hysterosalpingography	220
• Important Ultrasound Findings in Gynecological Disease	222
• Barrier Methods of Contraception	223
• Injectables and Implants Contraceptions	225
• Oral Contraceptives Pills	226
• Types of Intrauterine Devices	228
• Uterine and Vaginal Prolapse	230
• Instruments-1	232
• Instruments-2	234
• Instruments-3	236
• Instruments-4	239
5. OPHTHALMOLOGY 250+ Images/Illustrations Covered	243-285
• Visual Acuity Measurement.....	245
• Ophthalmological Test.....	247
• Refractive Types of Astigmatism and Correction.....	250

• Layers of Retina.....	251
• Layers of Cornea (Anterior to Posterior).....	252
• Clinical Images.....	253
• Type of Conjunctivitis Associated with Organisms.....	256
• Sequences of Visual Field Defects in Glaucoma.....	257
• Cranial Nerve Palsy	258
• Signs in Grave's Ophthalmopathy	259
• Types of Cataract.....	260
• Disorders of Lashes	261
• Fungal Keratitis.....	262
• Ocular Findings in Ocular Sarcoidosis.....	263
• Cotton-Wool Spots.....	263
• Fundoscopic Findings.....	265
• Dots and Spots in Ophthalmology.....	268
• Rings in Ophthalmology.....	271
• Lines in Ophthalmology	274
• Nodules in Ophthalmology.....	276
• Signs in Ophthalmology.....	277
• Imaging in Ophthalmology	280
• Instruments.....	281
6. ENT 70+ Images/Illustrations Covered	287-309
• Radiographic View of Temporal Bone.....	289
• Interpretation of Tuning Fork Tests.....	292
• Symbols Used While Plotting the Audiogram	293
• Pure Tone Patterns.....	294
• Brainstem Evoked Response Audiometry/Auditory Brainstem Response (BAEP/BERA/ABR).....	295
• Clinical Test	296
• Epley's Maneuver.....	298
• Signs in ENT.....	298
• ENT Instrument.....	307
7. PREVENTIVE AND SOCIAL MEDICINE (PSM) 100+ Images/Illustrations Covered	311-350
• Important Instruments	313
• Health Hazard Symbols	315
• Pesticides Color.....	318
• Medical Entomology	318
• Immunization	321
• Important National Health Programs	324
• Maternal and Child Health Programs.....	329
• Suraksha Clinics.....	335
• International Organization	337
• Demographic Cycle	340

• Representation of Data	341
• Skewness of Curves	345
• Personal Protective Equipment (PPE)	346
• Biomedical Waste Management	349
8. ANESTHESIA 80+ Images/Illustrations Covered	351-383
• Anesthesia Machine.....	353
• Mallampati Score.....	355
• Anesthetic Circuits	356
• Flow Meter Assembly	358
• Laryngoscopy	359
• Oropharyngeal Airway.....	361
• Laryngeal Mask Airway (LMA).....	362
• Endotracheal Tube	363
• Venturi Mask.....	365
• Oxygen Therapy.....	366
• Color Coding of Medical Gas Cylinders	370
• Stages of General Anesthesia	374
• Catheters	376
• Color-Coding of IV Cannulas	378
• Lumbar Puncture	379
• Waveform Capnography.....	382
• Different Waveform Capnography	383
9. DERMATOLOGY 200+ Images/Illustrations Covered	385-437
• Layers and Cells of Epidermis.....	387
• Primary Skin Lesions.....	388
• Secondary Skin Lesions.....	392
• Special Skin Lesions.....	394
• Important Instrument and Test for Diagnosis of Dermatological Disorder	395
• Disorders of Dermoepidermal Junction.....	397
• Bullous Pemphigoid versus Pemphigus Vulgaris.....	398
• Dermatitis	400
• Erythema.....	403
• Lichen Planus	405
• Psoriasis.....	407
• Leprosy	409
• Pityriasis Rosea.....	412
• Cutaneous Tuberculosis.....	413
• Pigmented Disorders.....	414
• Skin Manifestations in Infective Disease.....	415
• Sexual Transmitted Infections.....	416
• Cutaneous Mycoses	421
• Clinical Clue in Dermatology.....	424

• Nail Findings.....	430
• Histological Findings in Skin Disorders.....	431
• Direct Immunofluorescence Findings.....	434
• Tongue Findings in Different Diseases.....	436
10. RADIOLOGY 100+ Images/Illustrations Covered	439-483
• Focused Assessment with Sonography in Trauma (FAST).....	441
• Ultrasound Findings of Lung.....	443
• Respiratory System Imaging.....	446
• Gastrointestinal Tract Imaging.....	456
• Cardiovascular Imaging.....	461
• Central Nervous System Imaging.....	464
• Musculoskeletal System Imaging.....	472
• Genitourinary Tract Imaging.....	478
• Women's Imaging.....	480
• Radionuclide Imaging.....	482
11. ORTHOPEDICS 150+ Images/Illustrations Covered	485-526
• Clinical Tests in Orthopedics.....	487
• Most Common Fractures in Orthopedics.....	490
• Most Common Bone Tumors.....	495
• Osteochondritis in Different Bones.....	497
• Bone Infection.....	500
• Fingers in Rheumatology.....	502
• Nerve Injury.....	504
• Types of Traction.....	507
• Important Casts and Spica.....	511
• Types of Splint.....	513
• Types of Brace and Collar.....	518
• Nail and Fixator.....	520
• Important Instrument-1.....	522
• Important Instrument-2.....	525
12. PSYCHIATRY 50+ Images/Illustrations Covered	527-539
• Important Dates in Psychiatry.....	529
• Sigmund Freud's Structural Theory of Mind.....	530
• Mini-Mental State Examination/Folstein Test.....	531
• Psychological Test for Assessment of Personality.....	532
• Non-Pharmacology Therapy in Psychiatric Disorder.....	533
• Clinical Test for Drug Addiction.....	535
• California Rocket Fuel.....	537
• Phases of Sexual Response Cycle.....	538
• Treatment of Alcoholism.....	539



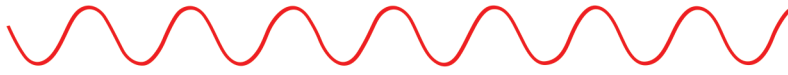
CBSPD

Dedicated to Education

MEDICINE

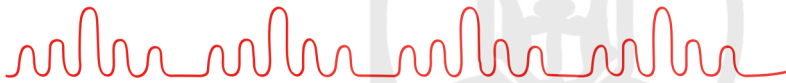
BREATHING PATTERNS

1. Normal Breathing




- Regular and comfortable.
- 12-20 beats per minute.

2. Cheyne-Stokes Respiration



- It is a disorder characterized by recurrent central apneas during sleep alternating with a crescendo-decrescendo pattern of tidal volume.
- Characterized by periods of apnea and hyperpnea
- The duration of one cycle is about 1 minute.
- Basic cause for Cheyne-Stokes respiration is the prolongation of circulation time from the lung to brain.
- Because of this, there is a long delay in response of chemoreceptors to the changes in PCO_2 .
- At the end of apneic episode, PCO_2 is the highest and PO_2 is the lowest.
- **Causes of Cheyne-Stokes respiration:**
 - Normally occurs during sleep at high altitude
 - Congestive cardiac failure
 - Damage to respiratory system.

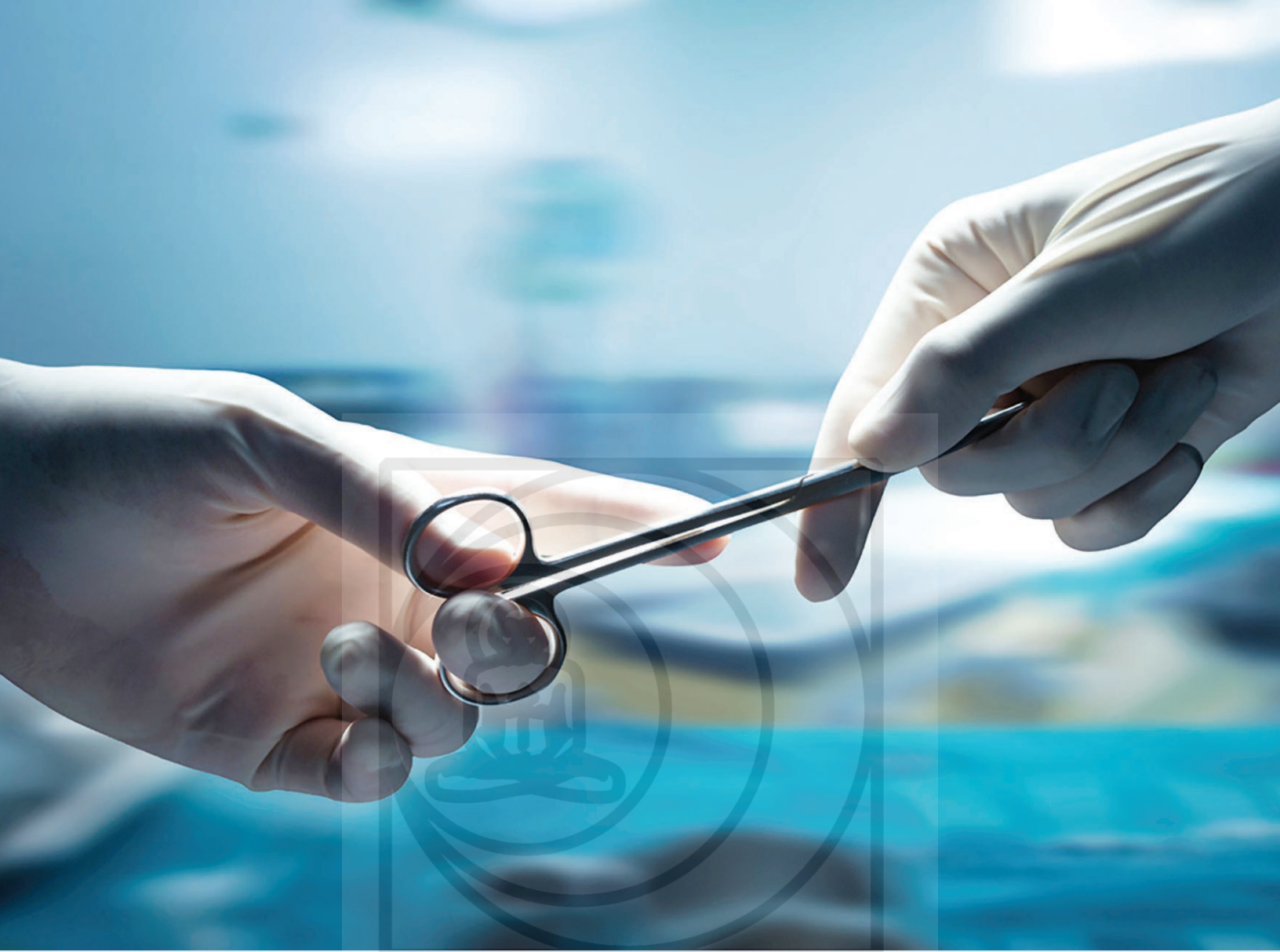
3. Biot's Breathing



- It is characterized by irregular periods of apnea alternating with periods in which four or five breaths of identical depth are taken.
- It is also called ataxic breathing.
- Characterized by highly irregular inspiration, often separated by long periods of apnea.
- Most commonly occurs in conditions causing damage to Medulla, increased intracranial pressure associated with spinal meningitis and other central nervous system disorders.

Dedicated to Education

CBSPPD

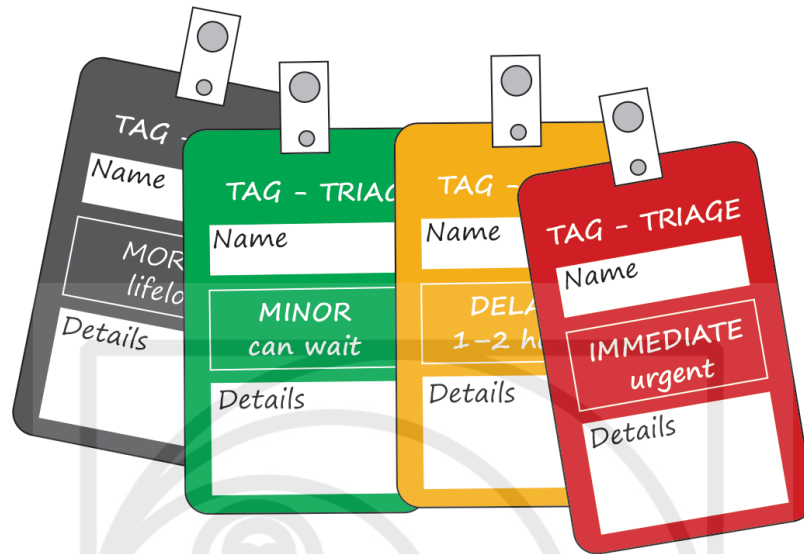


CBSPD

Dedicated to Education

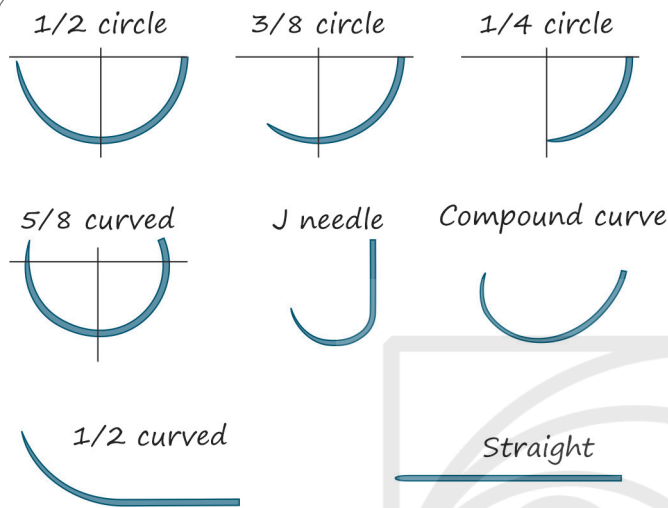
SURGERY

TRIAGE CATEGORIES



Priority	Medical need	Color	Clinical status	Examples
First (I)	Immediate	Red	Critical, but likely to survive if treatment is given early	<ul style="list-style-type: none"> Tension pneumothorax Severe facial trauma Extradural hematomas Hemothorax Profuse external bleeding Major intra-abdominal bleed Flail chest
Second (II)	Urgent	Yellow	Critical, likely to survive if treatment is given within hours	<ul style="list-style-type: none"> Pelvic fractures Degloving injuries Compound fractures Spinal injuries Ruptured abdominal viscus
Third (III)	Nonurgent	Green	Stable, likely to survive even if treatment is delayed for hours to days	<ul style="list-style-type: none"> Minor lacerations Sprains Simple fractures
Last (O)	Unsalvageable	Black	Not breathing, pulseless, so severely injured that no medical care is likely to help	<ul style="list-style-type: none"> Severe brain damage Major disruption/loss of chest or abdominal wall structures Very extensive burns

TYPES OF NEEDLE



- **Round bodies:** Separate tissue fibers while entering instead of cutting. Commonly used in gastrointestinal (GI) and cardiovascular anastomosis.
- **Conventional cutting needles with cutting edge inside (Reversed cutting—cutting edge is outside):** These are used for tough tissues like fascia and skin.
- **Blunt needles:** Closure of abdominal wall in the case of transmitted disease like HIV.
- **Straight needle:** Skin closure.
- **Half circle needles:** Most common use in GI tract.
- **J Needle:** Vagina.
- **Quarter circle needle:** Eye.
- **Compound curvature needle:** Oral cavity.

SUTURE TYPES

Sutures (According to Nature of Absorption)

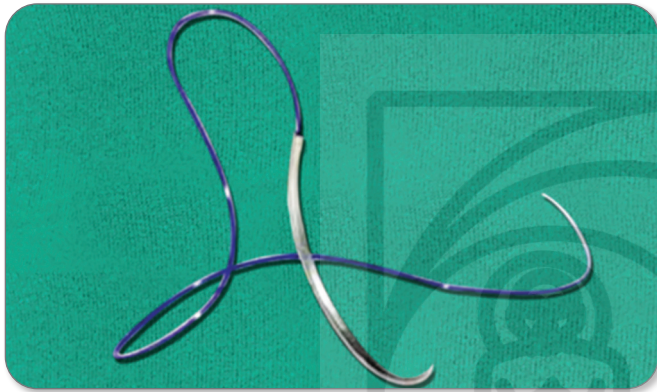Absorbable	Nonabsorbable
<ul style="list-style-type: none"> • Polyglactin (Vicryl): Most common used • Polyglycolic acid (Dexon) • Polydioxanone (PDS) • Poliglecaprone (Monocryl) • Plain catgut • Chromic catgut • Polyglyconate 	<ul style="list-style-type: none"> • Polypropylene (Prolene) • Polyamide (Ethilon = Nylon) • Polyester (Ethibond) • Silk • Linen • Surgical steel

Sutures (On the Basic of Material Structure)

Monofilament	Multifilament
<ul style="list-style-type: none"> • Made-up of single strand and hence will slip easily • As it is monofilament, risk of bacterial contamination is less • Examples: <ul style="list-style-type: none"> ◦ Prolene ◦ Polyamide (Ethilon) ◦ Catgut 	<ul style="list-style-type: none"> • Made-up of multiple strands and hence knotting will be strong • Bacterial contamination is so high in between the fibers • Examples: <ul style="list-style-type: none"> ◦ Silk ◦ Polyglycolic acid (Vicryl)

Polypropylene

- Blue in color.
- Synthetic and nonsynthetic absorbable suture material.
- Monofilament material.
- Commonly used for tissue repair, abdominal wall closure, hernia repairs, etc.
- Used in vascular anastomosis and rectus midline closure.



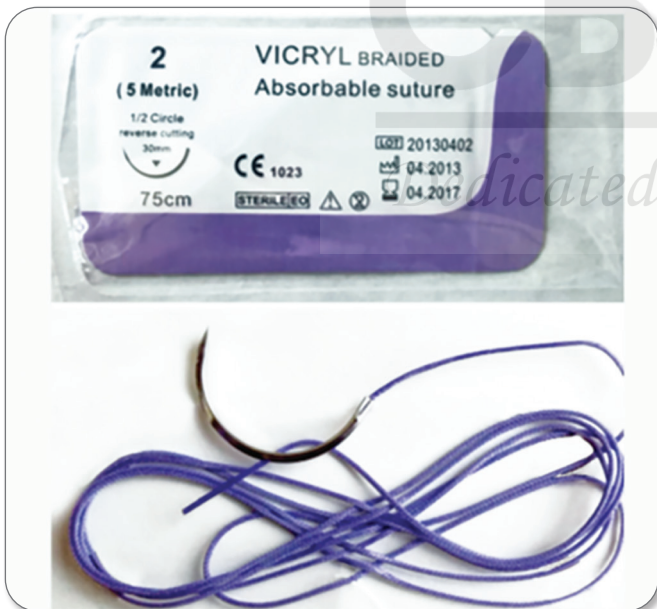Polypropylene

Vicryl

- Violet in color.
- Synthetic absorbable suture material.
- Used in bowel anastomosis and subcuticular sutures.

Note:

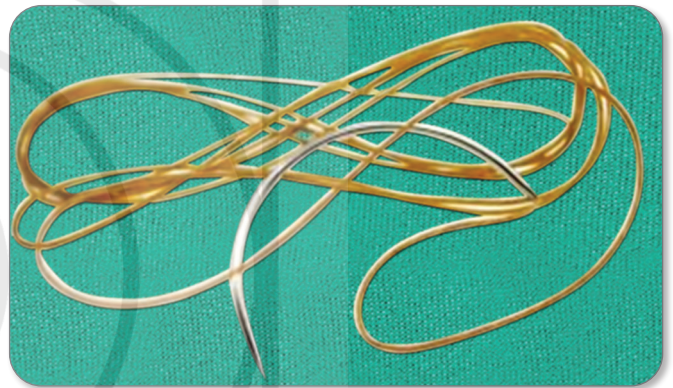
In subcuticular sutures, monocril (poliglecaprone) is better than vicryl.



Vicryl

Catgut Suture

- Brown in color.
- Derived from sheep GIT mucosa and processed and stored in isopropyl alcohol.
- Natural absorbable suture.
- Tensile strength is 21–28 days.
- Degradation happens by phagocytosis and enzymatic degradation and complete absorption happens in 90 days.
- High tissue reaction is seen with plain catgut.
- Used to ligate superficial vessels, subcutaneous closures, stomas and other tissues that heal rapidly.



Catgut suture

Uses of Various Sutures

Clinical condition	Suture material used
Vascular anastomosis	Prolene
Esophageal anastomosis	Nonabsorbable suture
Bowel anastomosis	Vicryl
Closing peritoneal cavity	Polydioxanone
Circumcision in children	Catgut
Suturing muscle and fascia	Chromic catgut
Hernioplasty	Prolene
Orthopedic surgery	Ethibond suture—made from braided polyester and coated with polybutylate for easier tying

Preservation of Suture

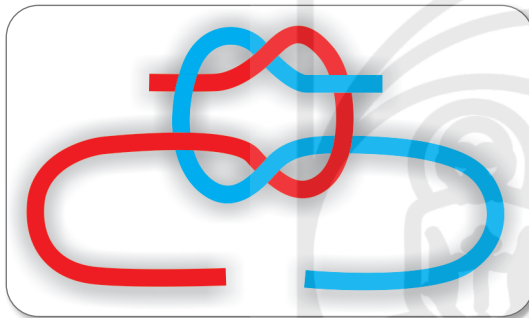
- Isopropyl alcohol—used as preservative while packing suture.
- Ethylene oxide—used in pasteurization of suture material.

Time of Suture Removal

Sutured area	Suture removal on
Eyelid, eyebrow, nose, lip and face	3-5 days
Scalp	6-8 days
Chest and abdomen	8-10 days
Ear	10-14 days
Back, extremities, hand and foot/sole	12-14 days

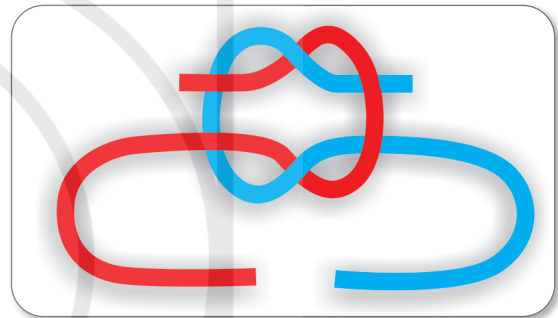
TYPES OF KNOT

Granny (Slip) Knot




In granny knot, the second knot (superior most) is seen to thread in the same direction as compared to the first knot. The knot is therefore not squared. This is slipping knot, helps to place the knot at exact site from a long distance. But it is not tight and hence we have to secure it with a square knot at the end. Granny knot will have colors crossing opposite (Example in 1st image: Red is on top in one and Blue is top on other).

Reef (Square) Knot



In reef (square) knot, two throws of opposite type made. Right side suture runs over the left and then left side suture runs over the right. This is a secure knot and gets tightened well. Square knot will have same color on the top (Example in 2nd image: Blue is on top).

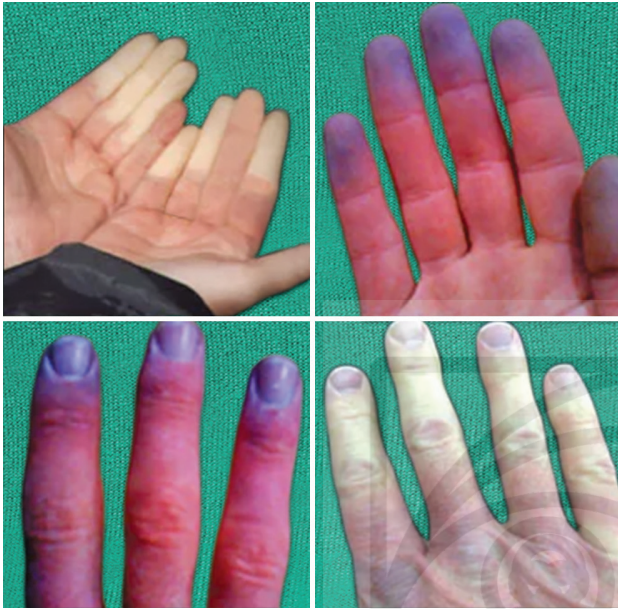Surgeon's Knot



For added security, two-throw technique of knots done and is advisable to prevent slippage.

Dedicated to Education

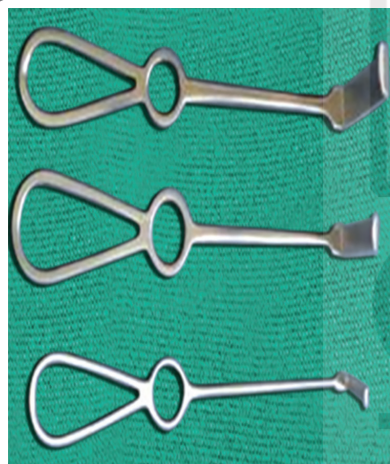Phenomenon Seen



- **W-B-C:** Initially limb color is White later Blue and then Crimson red.
- **White:** Due to spasm of both arteries and veins.
- **Blue (cyanotic phase):** Here arteries are still in spasm and veins and capillaries open.
- **Crimson red:** Arteries open in an extensive way, veins already in opened state.

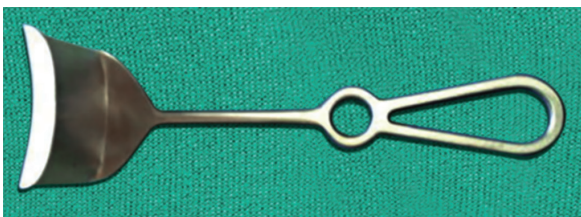SURGICAL INSTRUMENT

Langenbeck Retractor




- Used to retract tissue during hernia surgery, appendicectomy, etc.
- Available in various sizes.

Morris Retractor



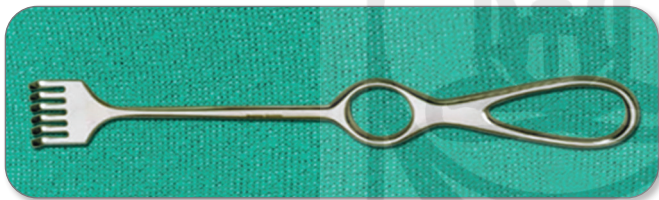- It is L-shaped.
- The handle and blade both are wider.
- Lower end of the blade is curved inward at right angle.
- **Uses:**
 - Used for tissue retraction during different operation. For example:
 - During appendicectomy to retract the layers of the abdominal wall.
 - During thyroidectomy to retract the strap muscle and sternocleidomastoid.
- Sterilization by autoclaving.

Czerny Retractor



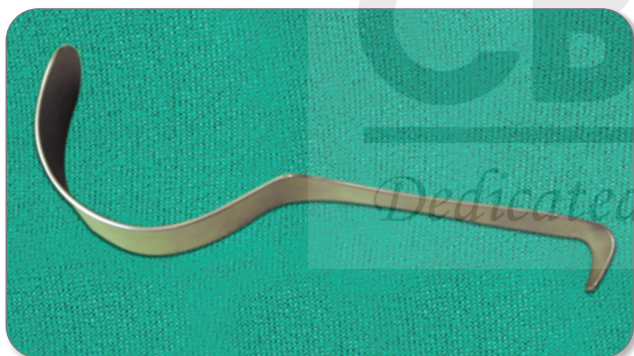- There is a flat blade at right angle to the shaft with the tip curved at the right angle while the other end has a biflanged hook.
- This is a superficial retractor.
- **Uses:**
 - Used to retract layers of the abdominal wall. Muscles during appendicectomy, herniorrhaphy or thyroidectomy.
- Sterilization by autoclaving.

Volkman Retractor



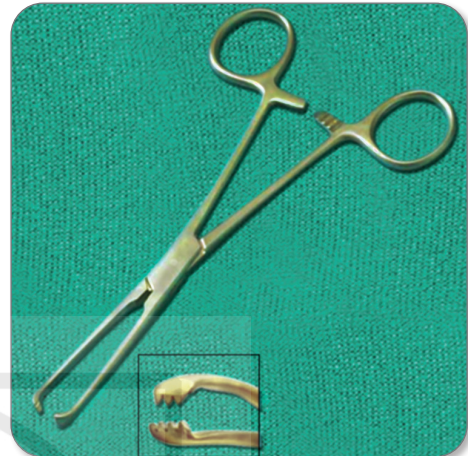- It has multiple hooks on one limb.
- Used to retract the skin flaps and fascia during operations on the surface level. For example: sebaceous cyst, lipoma and dermoid cyst.

Deaver Retractor



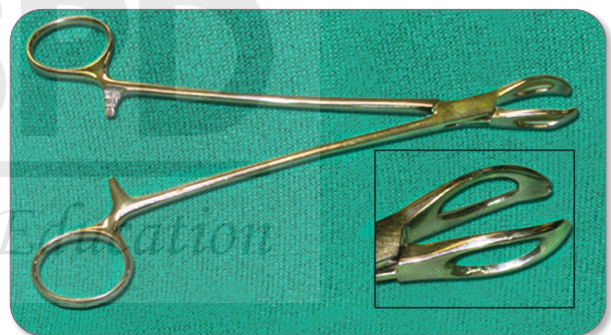
- It is S-shaped large curved retractor.
- **Uses:**
 - During cholecystectomy for retraction of right lobe of liver.
 - During gastrectomy for retraction of liver.
 - During pancreaticojejunostomy for retraction of stomach.
 - During kidney operation to retract the abdominal wall.

Allis Forceps



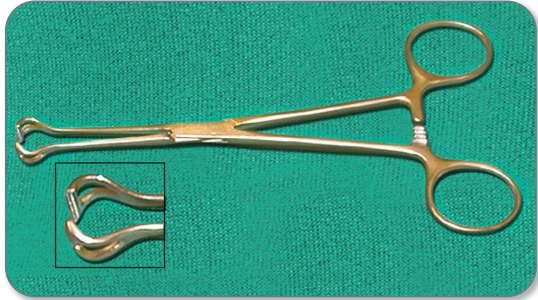
- The blades are longer and there is a gap between the blades which can accommodate some amount of tissue.
- The tips of the blades are provided with sharp teeth with grooves in between teeth of one blade get fits in the groove of the outer blade and vice versa then the ratchet is closed.
- **Uses:**
 - To hold the tough structures, like rectus sheath, muscle during abdominal surgery.
 - Linea alba is held up by Allis forceps during suturing.
 - Used to hold skin margins during incisional hernia operation to raise the skin flap.
- Sterilization by autoclaving.

Lane Forceps



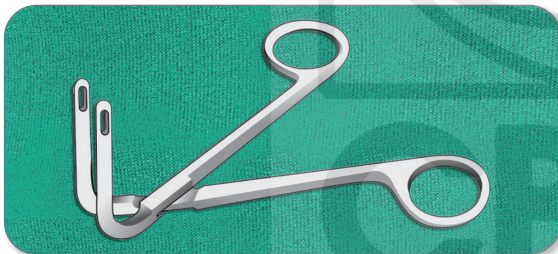
- This is a thick and heavy instrument; the terminal parts of the blades are curved and fenestrated.
- At the tip, there is a heavy tooth in one blade with groove in the other blade.
- The tooth fits into groove when ratchet is closed.
- **Uses:**
 - During submandibular or parotid gland excision.
 - During mastectomy, it may be used to hold the breast while dissecting it off from the pectoral fascia.

Babcock Forceps



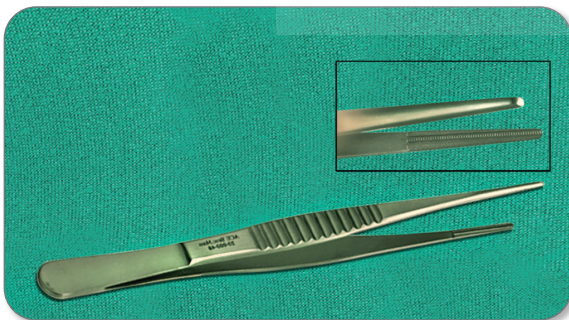
- Terminal parts of the blades are curved and fenestrated.
- The tip is provided with a ridge in one blade and groove in the other.
- When ratchet is closed, the ridge of one blade fits into the groove of the other blade.
- The fenestration in the blade allows some graft tissue to be accommodated in the hollow while holding it.
- **Uses:**
 - To hold the tubular soft tissue, e.g., appendix during appendicectomy; fallopian tube during tubal ligation.
 - To hold intestine during resection and anastomosis operation.

Irwin Pyelolithotomy Forceps



It is used to hold the stone during nephrolithotomy, pyelolithotomy or ureterolithotomy.

DeBakey Grasping Forceps



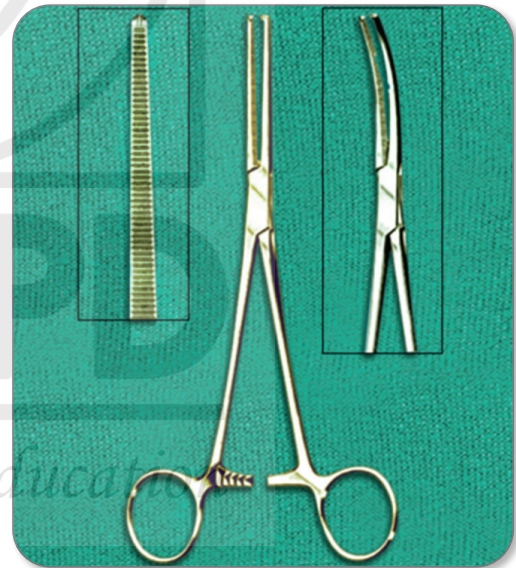- Used to grasp the tissue during suturing.
- Holds the opposing edges tightly while suturing.
- Used in vascular anastomosis, bowel anastomosis.

Toothed Dissecting Forceps

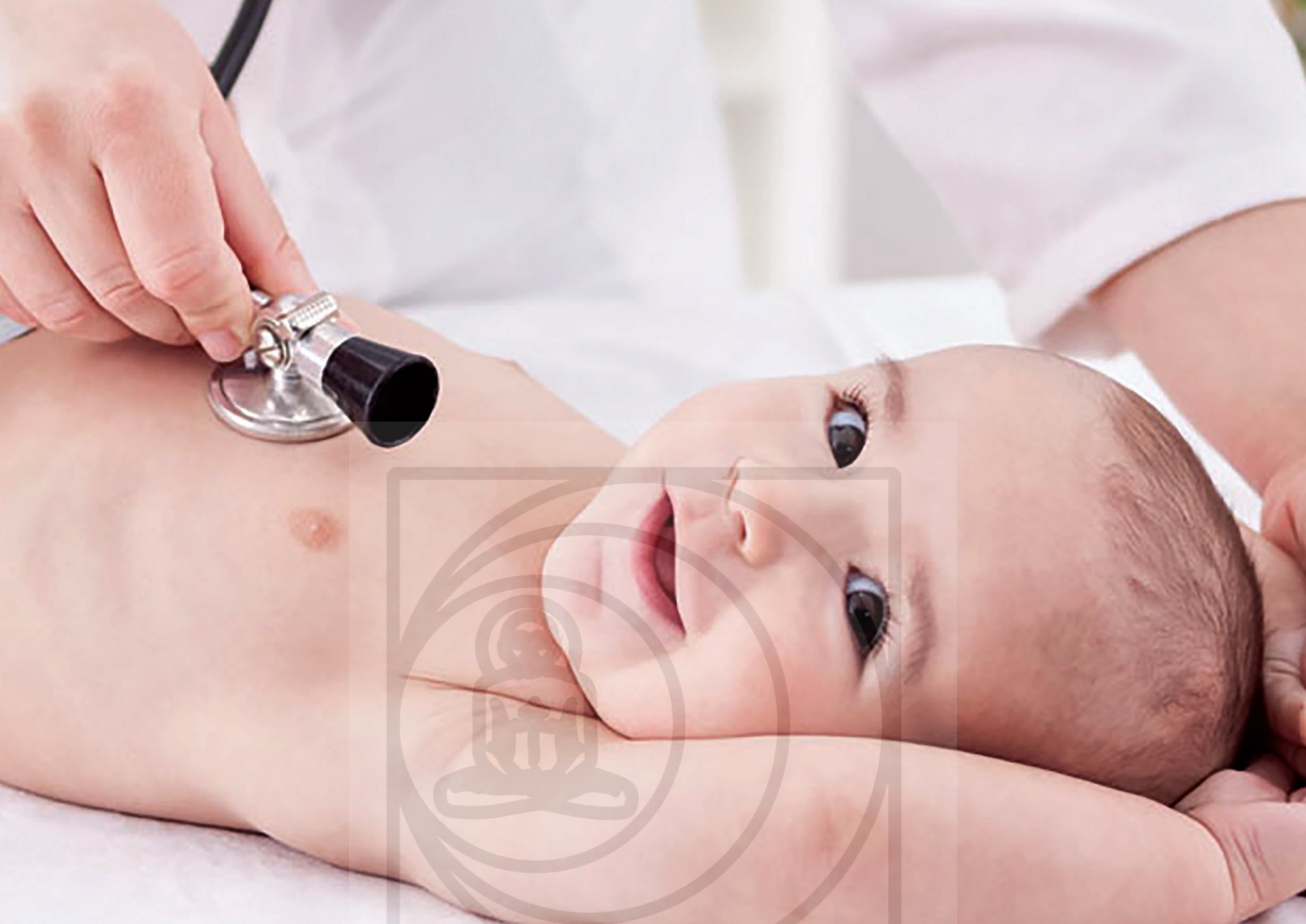

- Same as DeBakey forceps but there is a tooth at the top of the one blade and a groove at the tip of the other blade.
- When the blades are approximated, the tooth fits into the grooves.
- Because of the tooth, there is better grip and hence less chance of slipping of tissue or suture.
- **Uses:**
 - Used during almost all operations to hold the tough structures like skin, fascia and aponeurosis.
 - Used to hold the linea alba or rectus sheath during closure of abdominal incision.
 - Used to hold the scalp during closure of scalp incision.

Kocher Artery Forceps



- Curved and straight artery forceps.
- Holds the structure very tightly.
- Never to be used in the bowel holding.
- Very commonly used instrument in surgery.
- Used to hold the bleeding vessels, dissections, etc.



CBSPD

Dedicated to Education

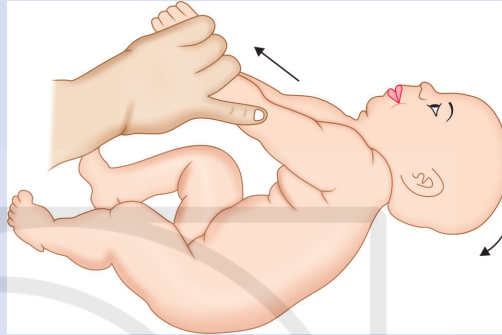
PEDIATRICS

MILE STONE DEVELOPMENT

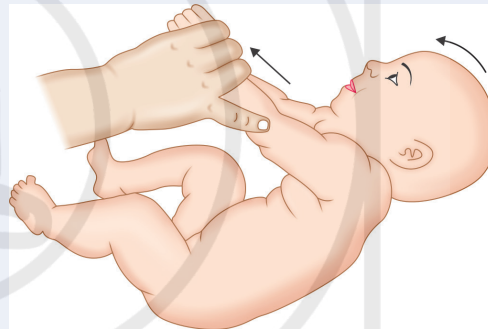
Developmental Assessment ('Gross Motor) During Initial Months of Infancy

Supine and 'pull to sit':
This examination is done to assess the control of head and examine the curvature of spine

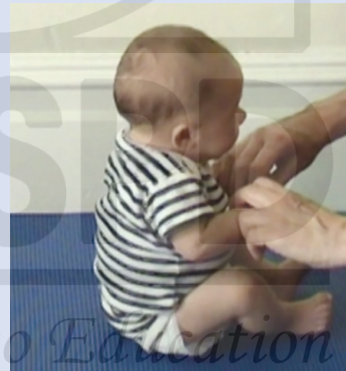Newborn: Complete head lag (as depicted below) and back (spinal curvature) is round



5 month: No head lag



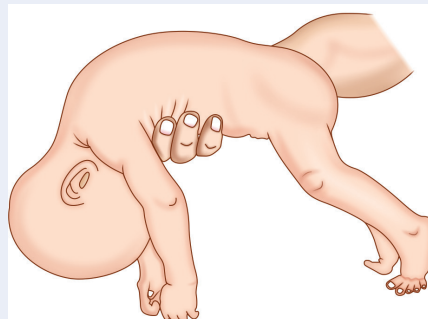
6 months: Back is straight (viz., with support, can sit with trunk erect)



Ventral suspension:

- Done by lifting the child from couch in the prone position (supporting the abdomen with examiner's hand)
- Done to assess head control

New born: Lack of head control (Head sag present)





Contd...

MARASMUS AND KWASHIORKOR

Features	Marasmus	Kwashiorkor
Image		
	Marasmus child shows voracious appetite.	Poor diet history and a swollen belly are suggestive of Kwashiorkor.
Concept	<ul style="list-style-type: none"> It is malnutrition which does not cause edema. Marasmus results in muscle wasting. 	Protein malnutrition resulting in skin lesions, edema due to decreasing plasma oncotic pressure, liver malfunction (fatty change due to decreasing apolipoprotein synthesis).
Etiology	Decreased intake of both proteins and calories and other nutrients	Decreased protein intake
Age	Seen in infants	Seen in older children (6 months to 3 years)
Incidence	More common	Less common
History		
Appetite	Good	Anorexia
Complementary feeding (weaning)	Early	Late
Clinical Examination		
Appearance	Old man appearance	Moon face
Sensorium/activity	Alert, playful, active/ apathetic	Apathy, dull, irritable
Weight	Less than 60%	60-80%
Edema	Absent	Present
Mentation	Alert	Apathy, irritable
Mood	Normal	Irritable
Hair changes	Absent/mild	Present(flag sign) ^o
		

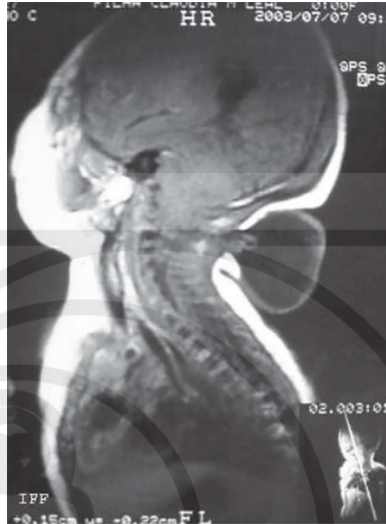
Contd...

Features	Marasmus	Kwashiorkor
Skin changes	Absent	Present (dermatosis, ulcers)
Muscle wasting	More (seen all over the body)	Less (seen only in the upper limbs as oedema masks wasting in the lower parts)
Organomegaly	Not present	Hepatomegaly (fatty liver)
Anemia	Moderate	More severe
Subcutaneous fat	Grossly reduced	Less reduced
Hormones		
Growth hormone	Normal/Increased	Increased
Cortisol	Increased	Increased
Insulin	Normal	Decreased
Glucagon	Normal/Variable	Normal/Variable
Thyroxine	Normal/Variable	Normal/Variable
Investigations		
Serum proteins/albumin	Reduced	Markedly reduced
Serum enzymes	Normal	Decreased
Vitamin A absorption	Normal	Markedly reduced
Duodenal enzymes	Normal concentration	Reduced
Serum enzymes amylase	Normal	Reduced
Urinary excretion	Increased	Low
Liver biopsy	No vacuolation	Fatty vacuolation
Complications	Less common and moderate	More common and severe
Response to treatment	Good	Variable
Mortality	More	Less
Image		

Nervous System

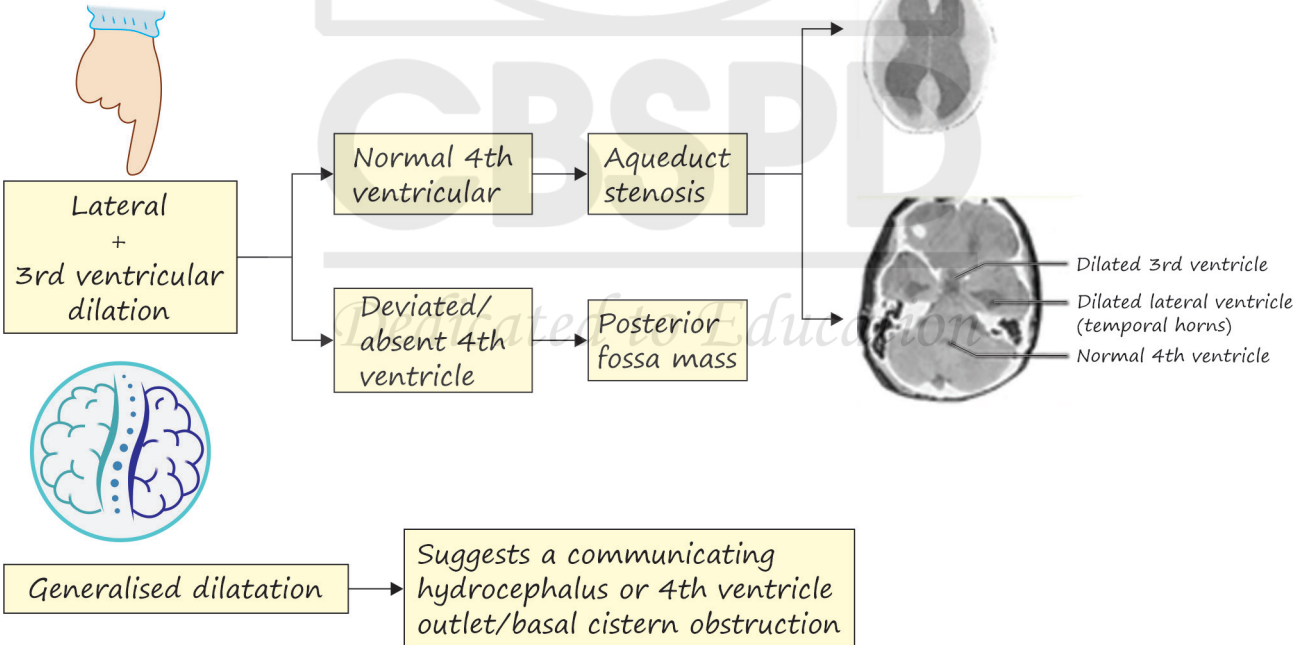
Arnold-Chiari Malformation

Arnold-Chiari Malformation is a defect of the hindbrain usually accompanied by myelomeningocele.

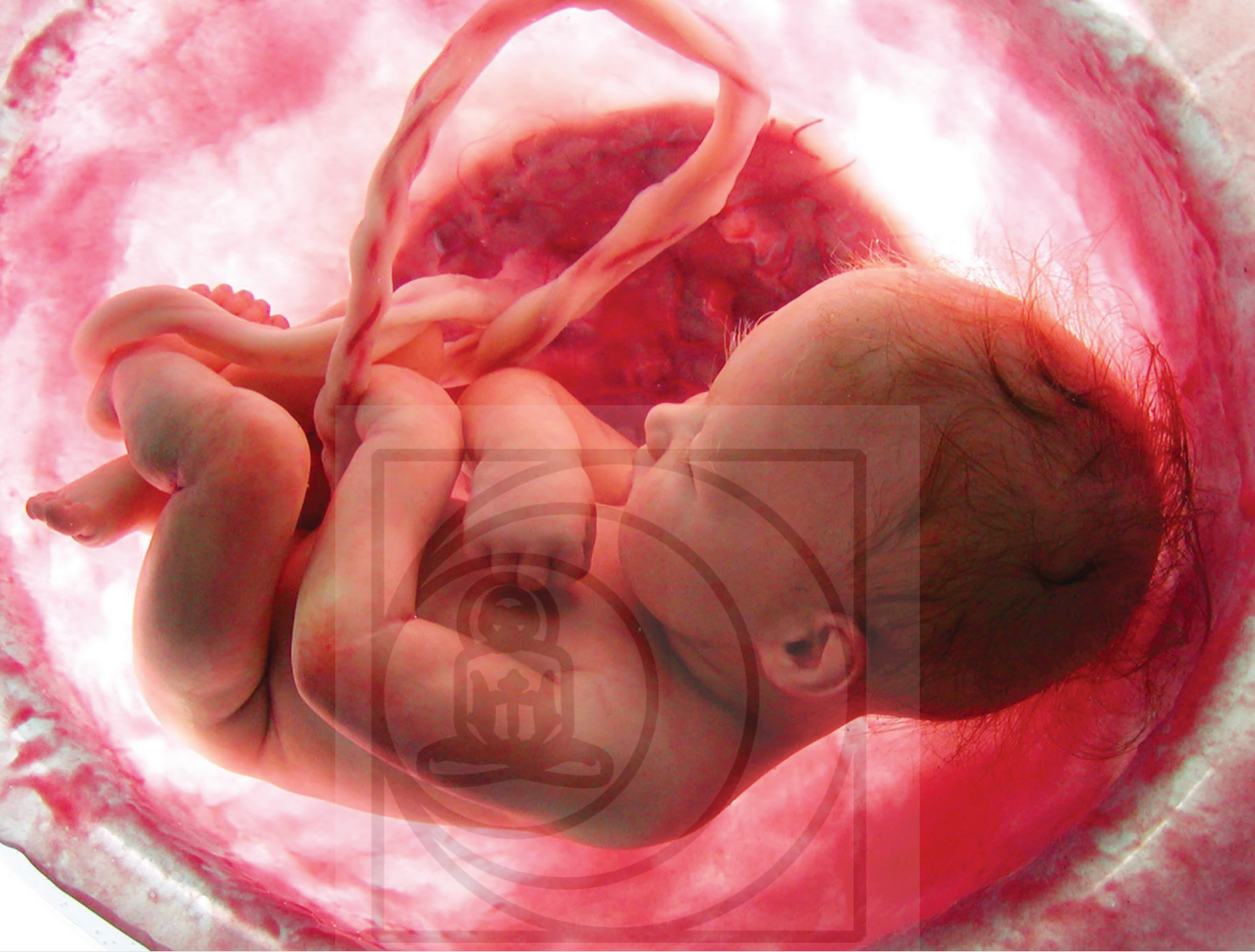


CT Scan-Hydrocephalus

The pattern of ventricular enlargement helps determine the cause, i.e.



1 = Periventricular lucency (if present) → Raised CSF
 Wide sulci → Ventricular dilation is due to atrophic process

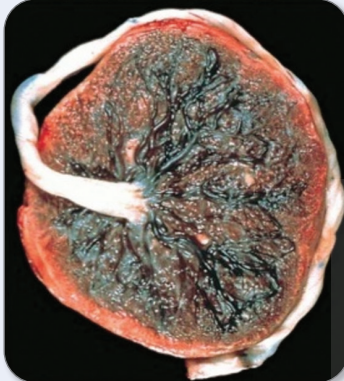




CBSPD

Dedicated to Education
**OBSTETRICS AND
GYNECOLOGY**

ABNORMALITIES IN PLACENTA

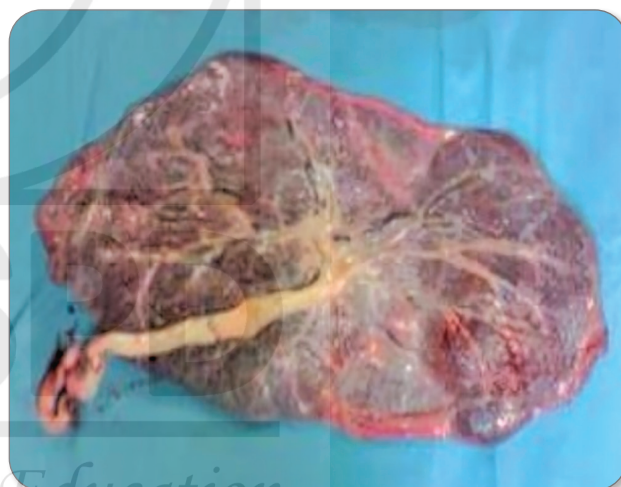Normal Placenta

Placenta	Fetal surface	Maternal surface
	<ul style="list-style-type: none"> Smooth, glistening and is covered by the amnion which is reflected on the cord. <div style="text-align: center;">  </div>	<ul style="list-style-type: none"> Dull grayish red in color and is divided into 15-20 cotyledons. <div style="text-align: center;">  </div>

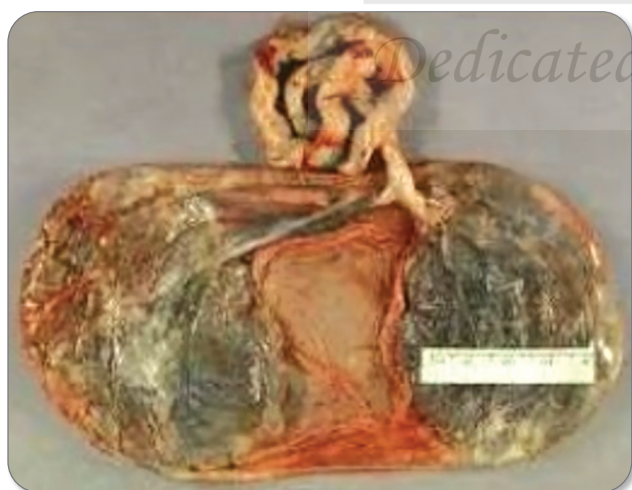Abnormalities of Placenta

Battledore placenta	Cord attached to margin of placenta
Furcate placenta	Blood vessels divide before reaching the placenta
Velamentous insertion	Blood vessels are attached to the amnion where they ramify before reaching placenta
Succenturiate placenta	Small part of placenta is separated from the rest
Circumvallate placenta	Deep insertion of placenta into the decidua

- Division is incomplete and vessels of fetal origin extend from one lobe to the other before uniting to form the umbilical cord.



Placenta Bilobata



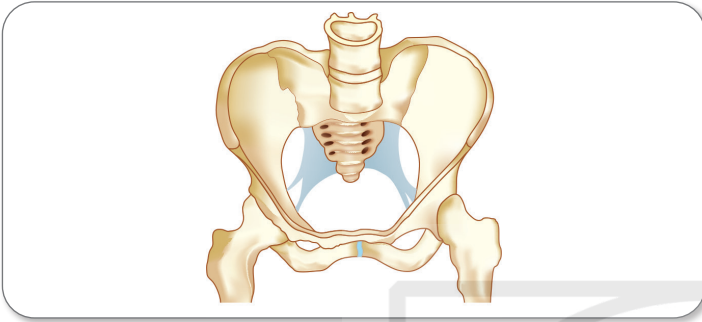
- The placenta is separated into lobes.

Placenta Succenturiata

- When one or more accessory lobes are situated away from the main placenta, but the two portions are connected by the membranes through which blood vessels run are called placenta succenturiata.
- How does it develop?**
Ans: When a part of chorionic leave is well developed (normally degenerate), it forms accessory lobes of placenta succenturiata.
- How will you diagnose placenta succenturiata?**
Ans: A small lobe attached with the membranes through which blood vessels run from small lobes

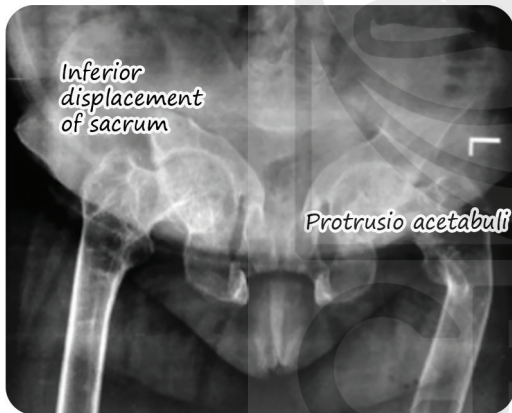
TYPES OF CONTRACTED PELVIS

Rachitic Flat Pelvis



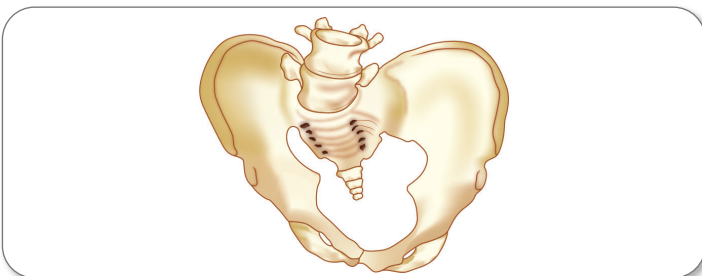
- Seen in rickets.
- Reniform shape of inlet with marked shortening of antero posterior diameter without affecting the transverse diameter.
- Sacrum is flat and tilted.
- Widening of transverse diameter of the outlet and pubic arch.

Triradiate Pelvis



- Seen in Osteomalacia and Severe rickets in adults (i.e., lack of calcium and vitamin D).
- Triradiate shape of inlet.
- Approximation of the two ischial tuberosities and marked narrowing of pubic arch.
- Short sacrum with coccyx pushed forward.

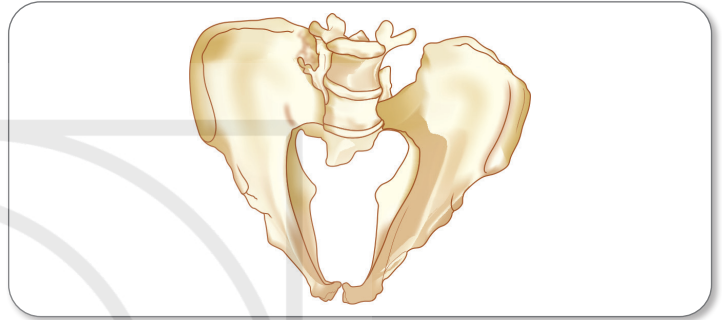
Naegele's Pelvis



- Congenital osteitis of sacroiliac joint.

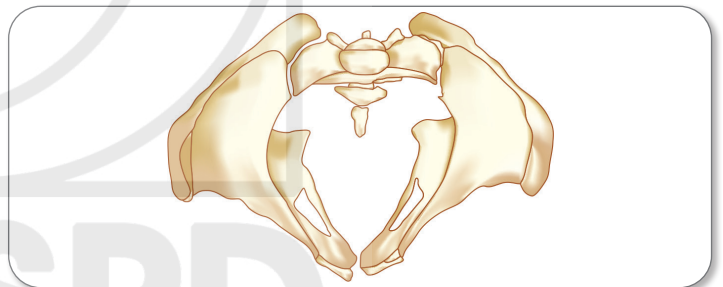
- One ala is absent, only one is seen.
- Remember: NALA, i.e., one ala present in Naegele's pelvis.
- Mode of delivery is by Cesarean section.

Robert's Pelvis



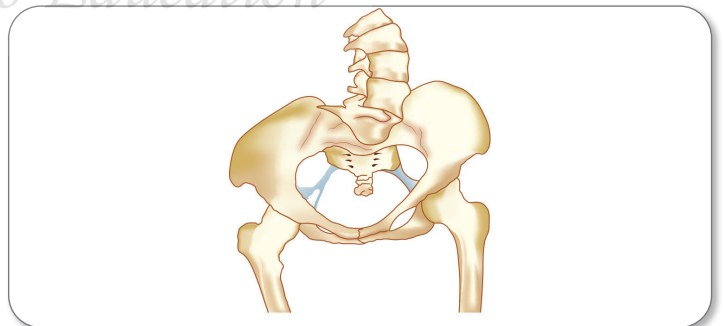
- Very rare.
- Both ala absent.
- Sacrum is fused with Innominate bone.
- Mode of delivery—by Cesarean section.

Funnel Shaped/Kyphotic Pelvis



- Seen in Tuberculosis or Rickets.
- Extreme funneling of the pelvis.
- Mode of delivery—by Cesarean section.

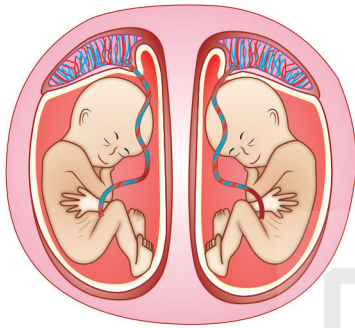
Scoliotic Pelvis



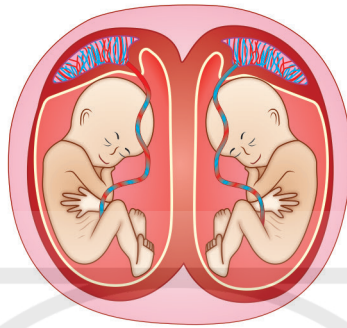
- Seen in Scoliosis of lumbar region.
- Acetabulum is pushed inward on the weight bearing sides.
- One of the oblique diameters is decreased.

MULTIPLE PREGNANCIES

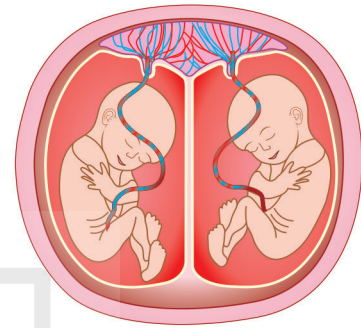
Relationships of the extraembryonic membranes in different types of twinning:



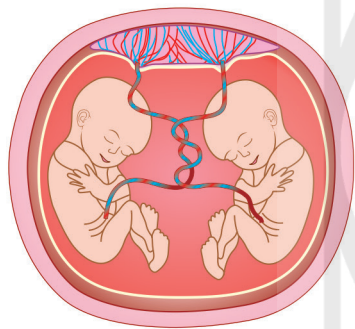
A Diamniotic, dichorionic separated



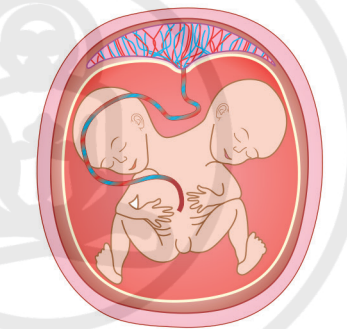
B Diamniotic, dichorionic fused



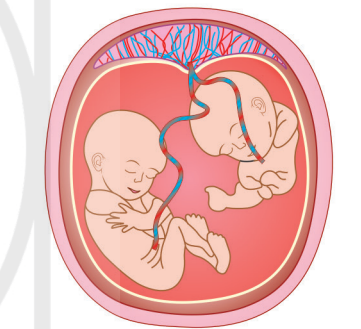
C Diamniotic, monoamniotic



D Monoamniotic, monoamniotic



E Incomplete separation of the embryonic axis results in conjoined twins



F Unequal division of the embryonic axis or unequal division of the blood supply may result in an acardiac monster

Time of division	Type of twin
0-72 hours	Dichorionic diamniotic
4-8 hours	Monoamniotic diamniotic
9-12 days	Monoamniotic monoamniotic
> 12 days	Conjoined twins

CLASSIFICATION OF FORCEPS DELIVERIES

Types of Forceps

- **Low forceps:** Fetal head is below +2 station, but has not reached the pelvic floor, rotation may be (a) $\leq 45^\circ$ or (b) $> 45^\circ$
- **Mid-forceps:** Fetal head is below 0 station, but has not reached +2 station
- **High-forceps:** Fetal head is unengaged, above 0 station. Not included in modern obstetrics classification because of the risk to both mother and fetus.

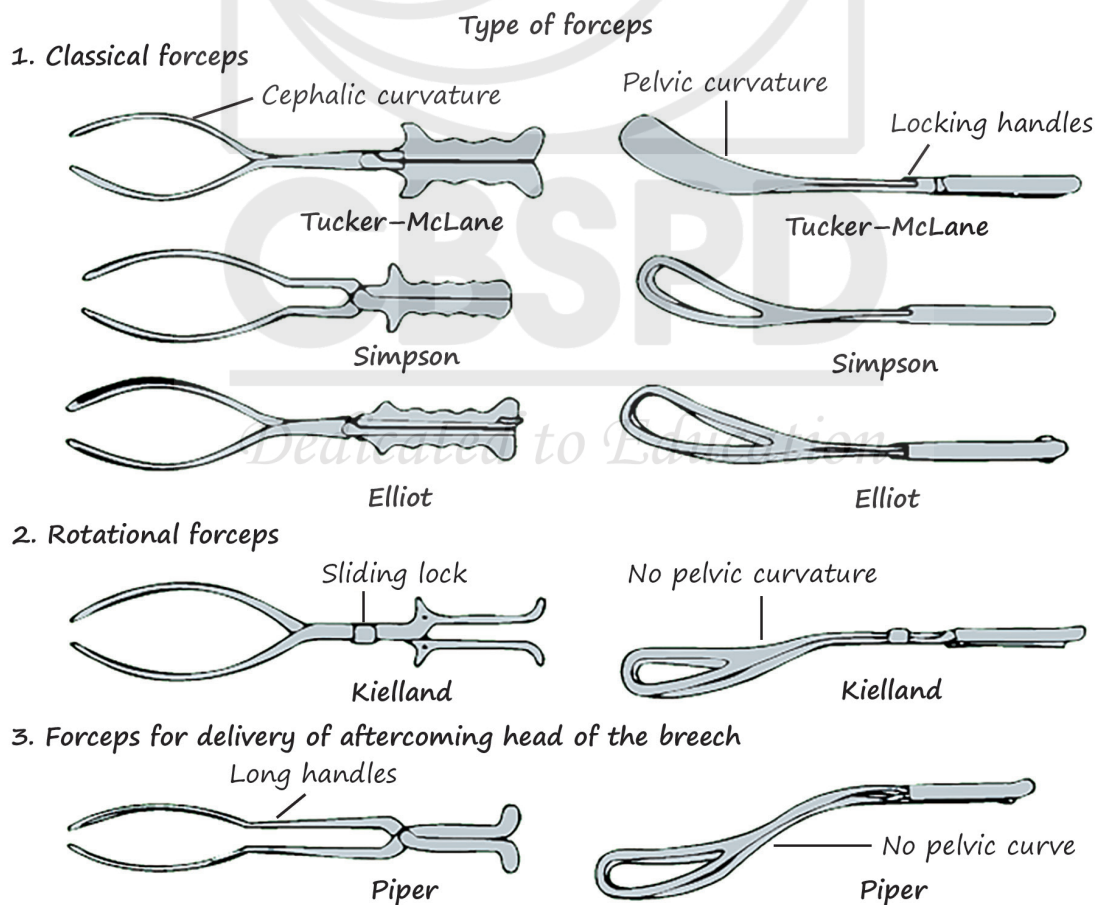
Indications

- **Prolonged second stage:**
 - This is the most common indication for forceps.
 - **In nulliparous female:** 3 hours with regional anesthesia or 2 hours without regional anesthesia
 - **In parous female:** 2 hours with regional anesthesia or 1 hour without regional anesthesia.
 - This may be because of dysfunctional labor or suboptimal fetal head orientation.

- **Category III EFM strip:** Fetal distress/non-reassuring fetal testing. The fetal heart rate monitor pattern suggests the fetus is not tolerating labor.
- **Avoid maternal pushing:**
 - Inadequate maternal expulsive efforts (such as women with spinal cord injuries or neuromuscular diseases)
 - Need to avoid maternal expulsive efforts (such as women with certain cardiac or cerebrovascular diseases)
- **Breech presentation:** Shorten the time to deliver the head of a vaginal breech fetus.

Obstetric Forceps

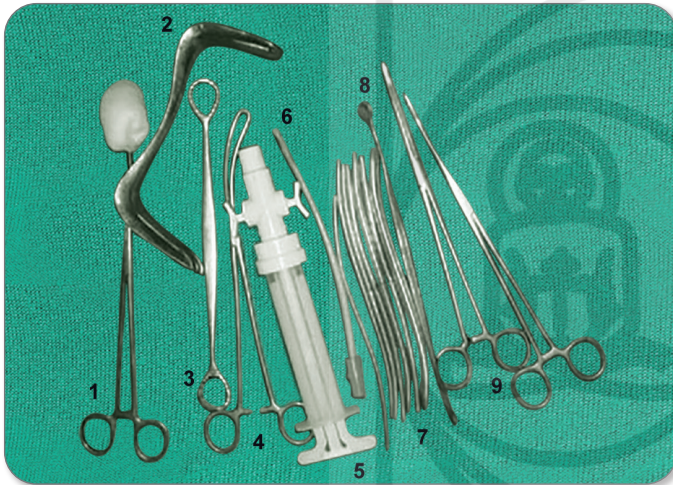
- **Classical forceps:** They have a pelvic curvature, a cephalic curvature, and locking handles. For example,
 - Simpson forceps: It is used for traction.
 - Tucker-McLane
 - Elliot



INSTRUMENTS-4

Instrument Tray for MTP

- Sponge holder for cleaning
- Speculum
- Anterior vaginal wall retractor
- Vulsellum
- Manual vacuum aspiration (MVA) syringe
- Cannula
- Hegar's dilators
- Uterine curette
- Sponge holder

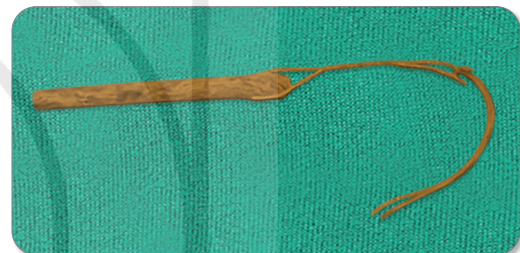

Laminaria Tent

- Made up of hygroscopic material derived from the stems of the seaweed called *Laminaria Japonica*. It swells up by absorbing fluids (hygroscopic) and is a slow dilator of cervix.

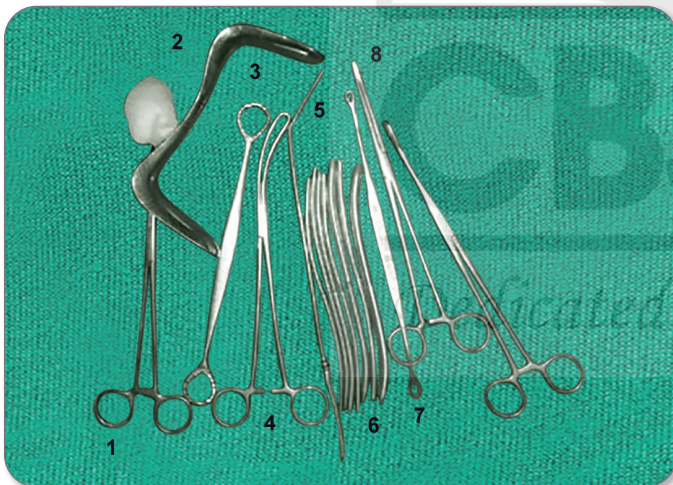Parts

- Stem is 5.5-6 cm
- Small, medium and large sizes are available according to the diameter
- A string is looped through one end and tied to gauze for easy removal.



- Two or three tents can be introduced side by side, if required into the cervical canal.
- Tents swell up to 3-5 times of their size after absorbing secretions of cervical canal in 12-24 hours and dilate cervix.
- Sterilized by dipping in absolute alcohol.

Instrument Tray for D and C

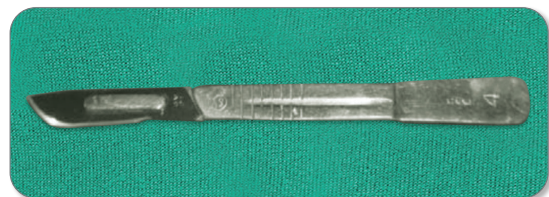

Uses

- First and second trimester pregnancy termination
- Expulsion of fetus in missed abortion, incomplete abortion
- Induction of labor.

Bard Parker's Knife

- Popularly known as surgeon's knife.
- It has a straight handle with a notch. Different sizes of blades can be attached with different sizes of handles. Larger sizes of blades are used for larger tissues and incisions. Smaller sizes of blades are used for finger incisions.



- Sponge holder for cleaning
- Speculum
- Anterior vaginal wall retractor
- Vulsellum
- Uterine sound
- Hegar's dilators
- Uterine curette
- Sponge holder

- The no. 10 scalpel blade is the most commonly used size. Acute angle of no. 11 blade is used for giving stab incisions for drains and in draining abscesses, e.g., Bartholin's abscess.



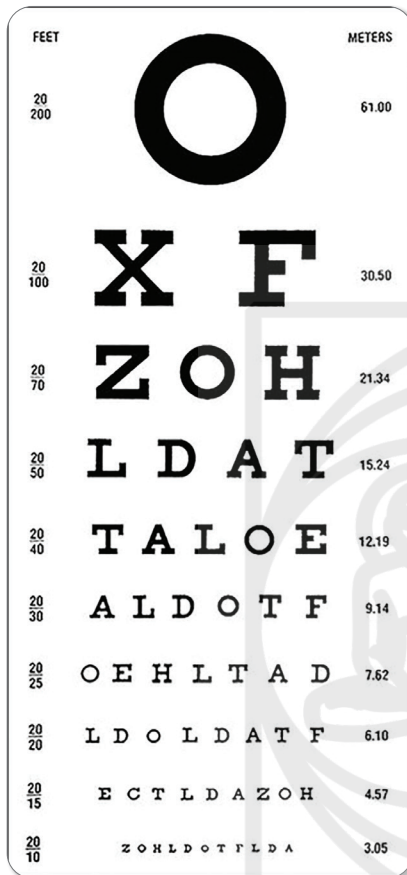CBSPD

Dedicated to Education

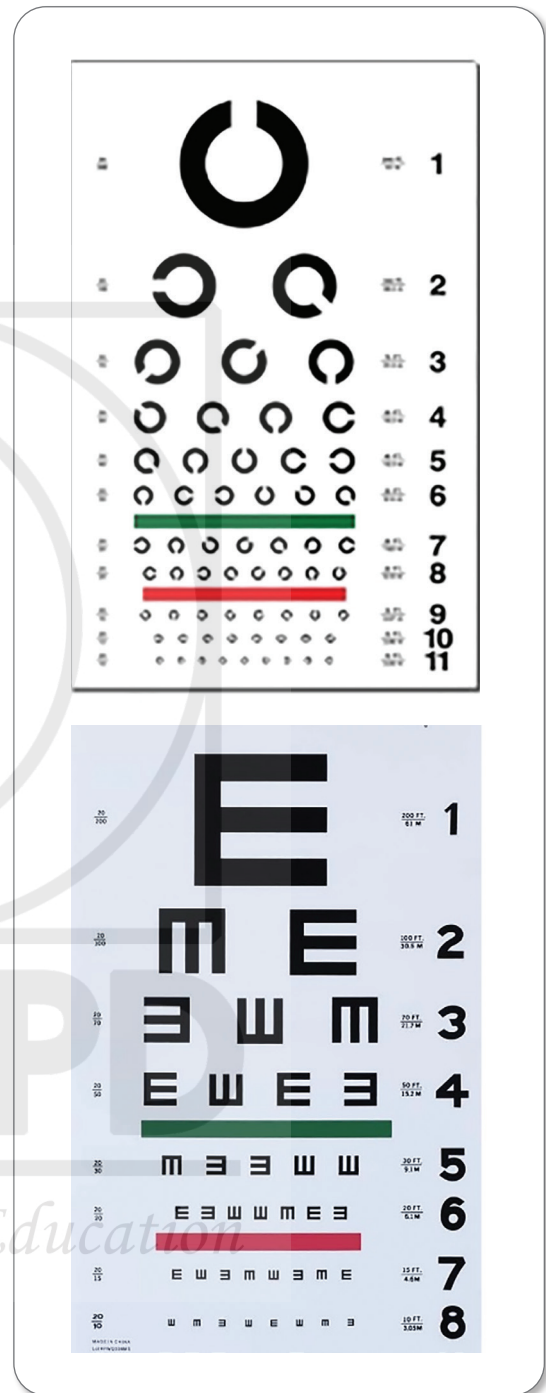
OPHTHALMOLOGY

VISUAL ACUITY MEASUREMENT

Snellen Chart

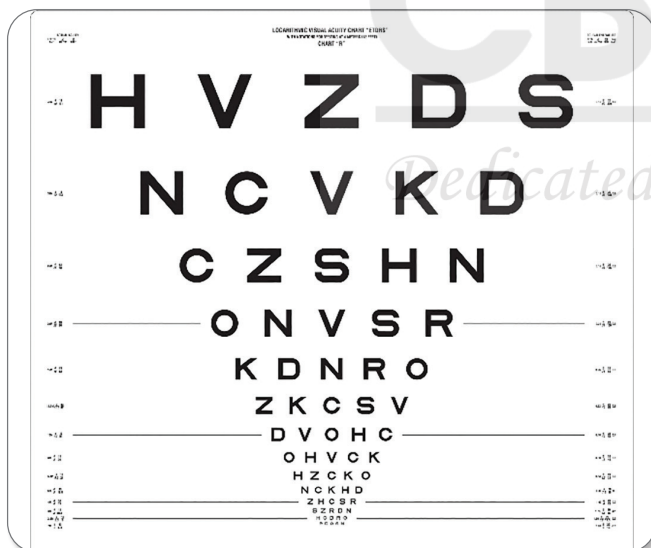


Landolt's C Ring Test and Snellen E-Chart Test



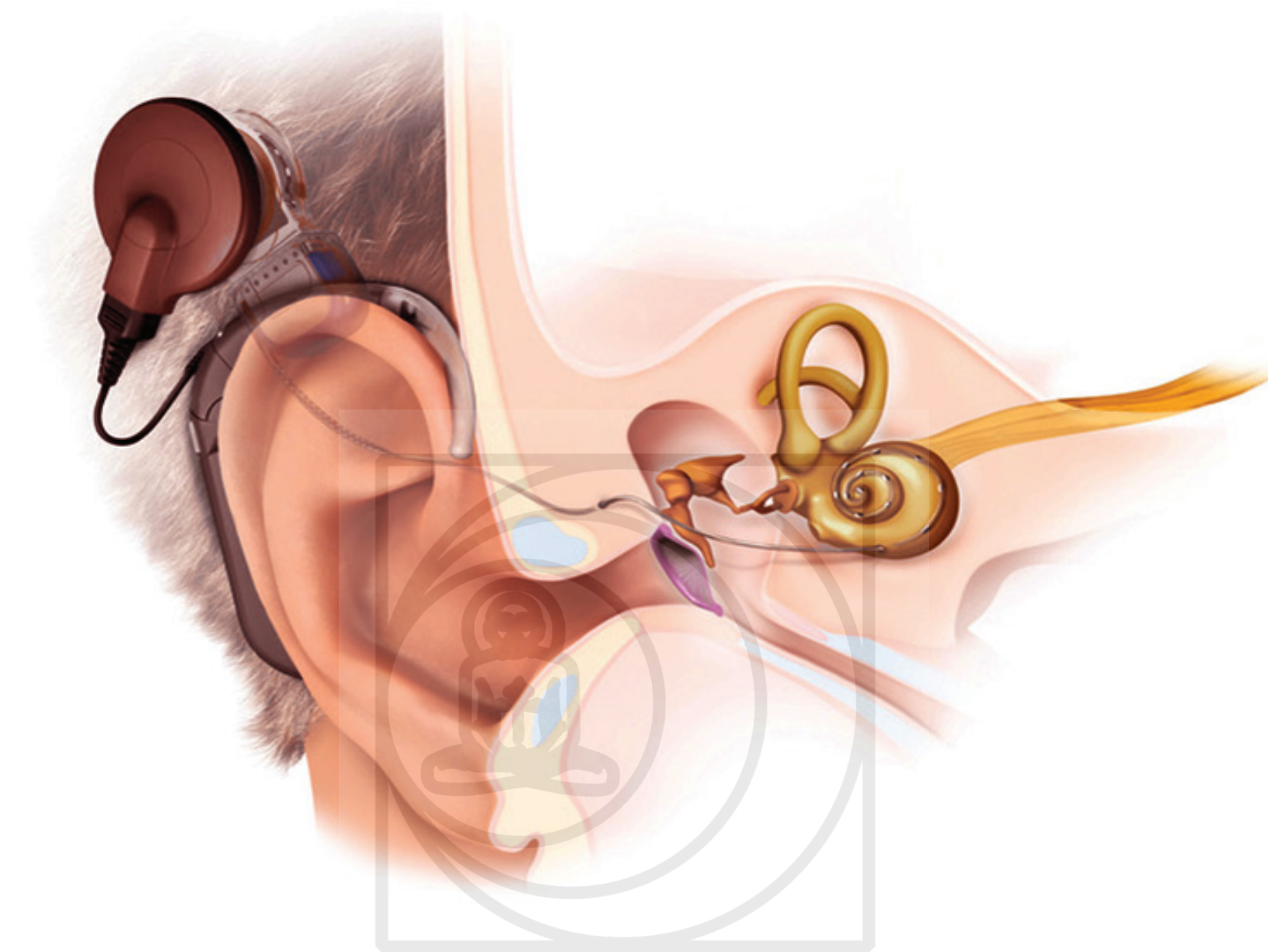
- Test for far vision.
- It measures minimum resolvable visual acuity.

LogMAR Chart-Bailey-Lovie and ETDRS Chart



- Chart determined on logarithm basis.
- Five letters in each row with 5:4 structure (height: breadth).

- It is used for illiterate adults.
- Same procedure and construction as Snellen chart, but consists of C (broken circle) or E instead of alphabet letters.
- Patient identifies the direction of opening of circle or open side of E, thus direction identification test.



CBSPD

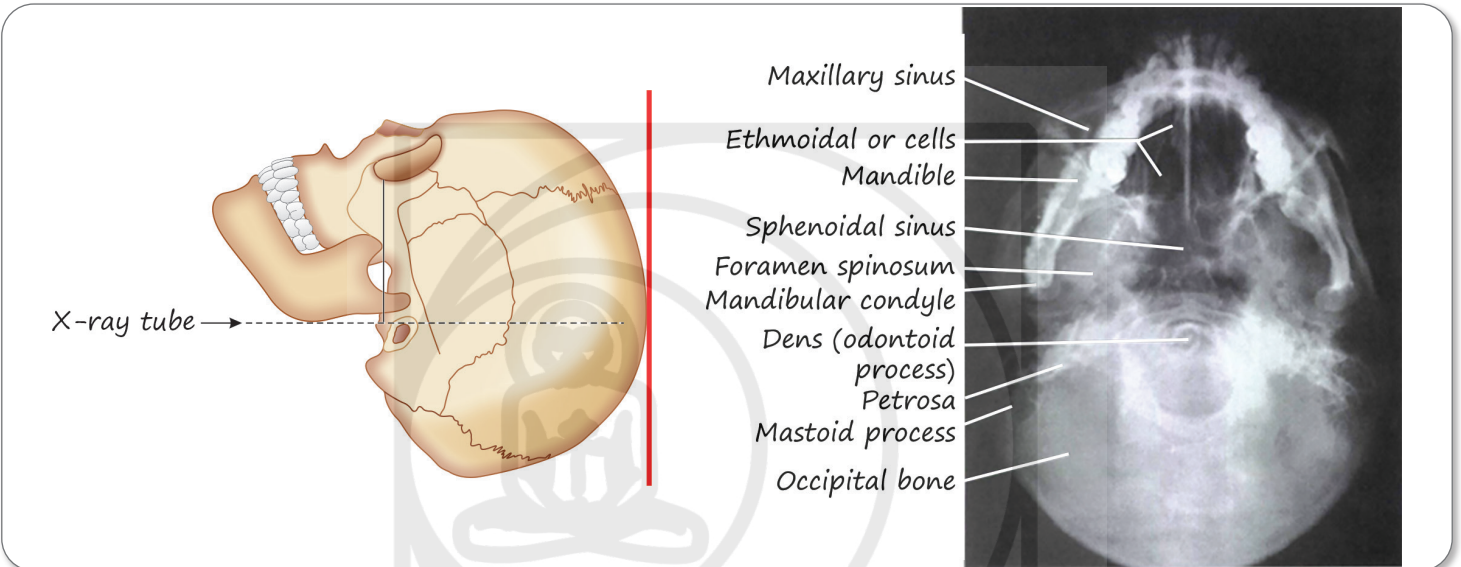
Dedicated to Education

ENT

RADIOGRAPHIC VIEW OF TEMPORAL BONE

Submentovertical View or Jug Handle View:

- This view is taken with vertex near the film and X-ray beam projected at right angles to the film from the submental area.
- The base view used for visualization of structure in the base of the skull and the structure of the skull which are oriented in a caudocephalad direction such as the anterior wall of the middle cranial fossa, lateral wall of the orbit and the lateral wall of the maxillary sinus.



- Optic foramina – progressive blindness
- Sella turcica – visual field defects

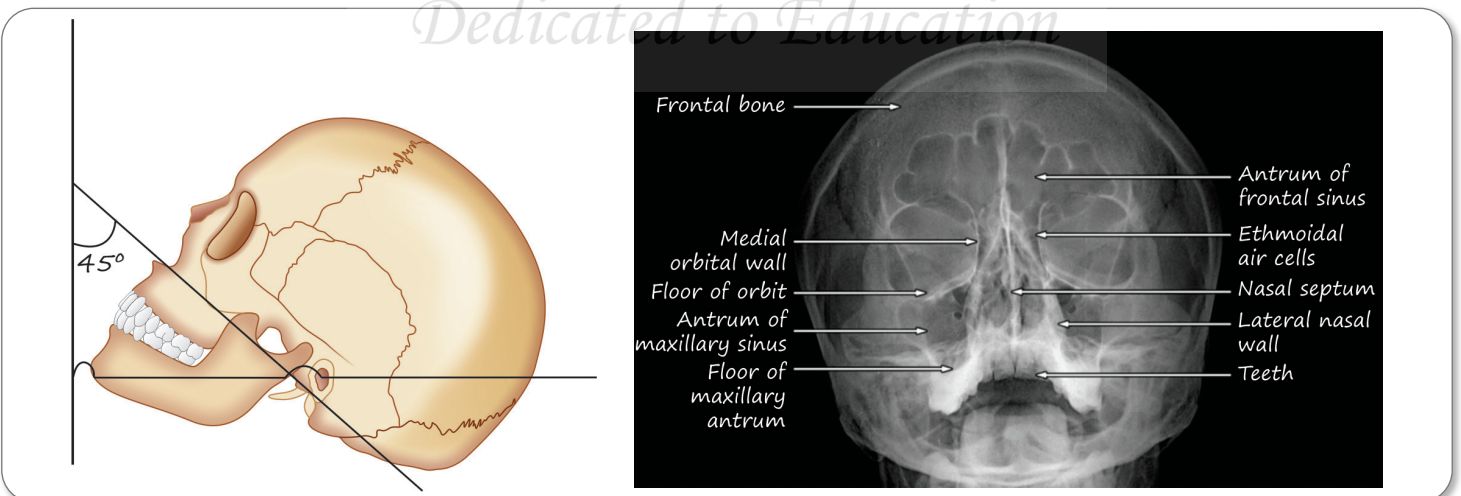
Key Note

“J”- shaped sella suggests optic nerve glioma. It can also occur congenitally in Hurler syndrome (α -mucopolysaccharidosis).

Petrous/internal auditory meatus – sensorineural deafness.

Water View

- Waters' view is also known as occipitomental view or inclined posteroanterior view. It is taken in such a way that nose and chin of the patient touch the film while X-ray beam is projected from behind.
- It is the best view for visualizing the maxillary sinuses and the anterior ethmoidal air cells.
- Structure visualized are: Floor of the orbit, anterior ethmoidal cells, frontal sinuses and maxillary sinus. Waters' view with open mouth is preferred as it also shows sphenoid sinus.



INTERPRETATION OF TUNING FORK TESTS

Rinne's Test

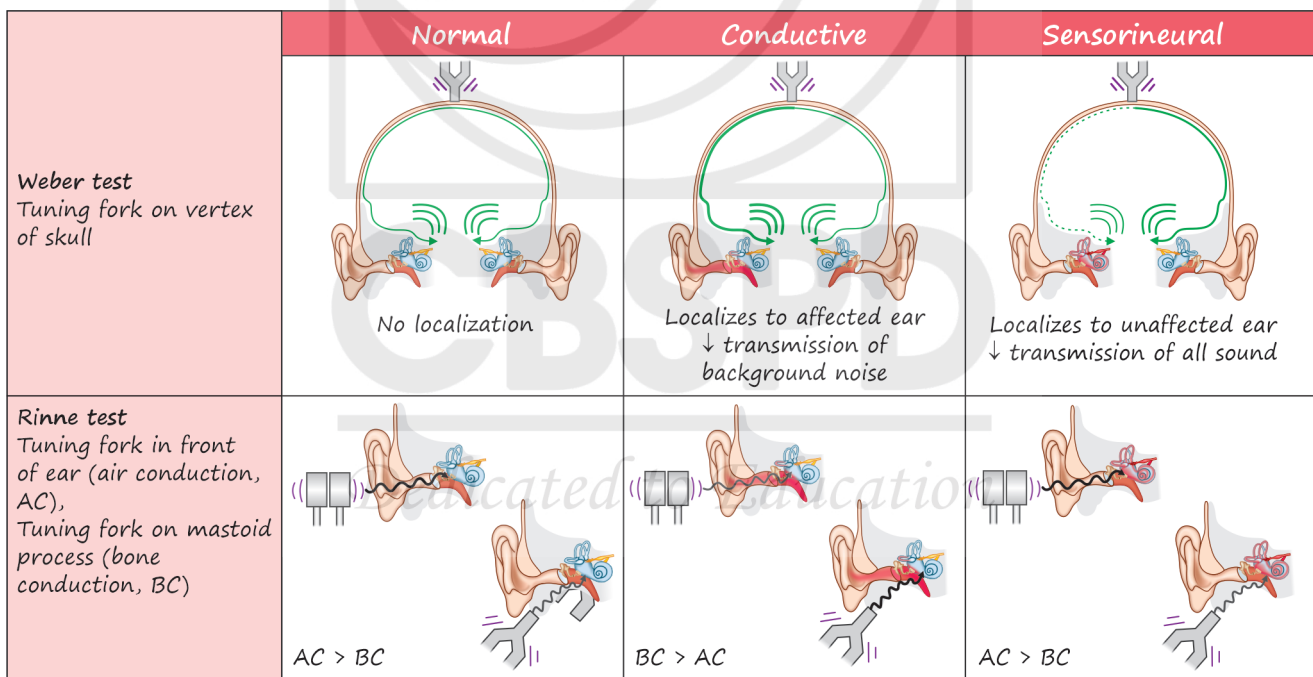
- In this test, air conduction (AC) of the ear is compared with its bone conduction (BC).
- Place a vibrating tuning fork of frequency 512 Hz on the mastoid process behind the ear until the patient can no longer hear the sound. The patient is using bone conduction during this phase of the test. Once the patient no longer hears the sound, the tuning fork is held in front of the ear. Normally, the patient still hears the sound using air conduction. Therefore, air conduction (AC) > bone conduction (BC) → Positive Rinne in a normal patient.
- Rinne test is called positive when AC is longer or louder than BC. It is seen in normal persons or those having sensorineural deafness.
- A negative Rinne (BC > AC) is seen in conductive deafness. A negative Rinne indicates a minimum air-bone gap of 15–20 dB.
- A prediction of air-bone gap can be made if tuning forks of 256, 512 and 1024 Hz are used.

Frequency Interpretation for Rinne Test

Frequency of tuning fork (Hz)	Minimum hearing loss for rinne to reverse (BC > AC, Negative rinne) (dB)
256	15
512	30
1024	45

Weber's Test

- In weber test, sound travels directly to the cochlea via bone.
- In this test, a vibrating tuning fork is placed in the middle of the forehead or the vertex.
- The patient is then asked which side is loudest.
- Normally, it is heard equally in both ears.
- In unilateral sensorineural deafness, sound is localized to the unaffected side.
- In unilateral conductive deafness, sound is localized to the affected side.
- Will only lateralize if difference in hearing loss between ears is >6 dB.



Diagnosing hearing loss

Clinical Pearls

- The Weber test is more sensitive in detecting CHL than the Rinne test.
- Weber test lateralization = ipsilateral conductive hearing loss or contralateral sensorineural hearing loss.

The Interpretation of Tuning Fork Tests

Examples	Weber test	Rinne test
Normal or bilateral SNHL	Central	AC > BC (+) bilaterally
Right-sided CHL, normal left ear	Lateralizes to right	BC > AC (-) right
Right-sided SNHL, normal left ear	Lateralizes to left	AC > BC (+) bilaterally
Right-sided severe SNHL or dead right ear, normal left ear	Lateralizes to left	BC > AC (-) right*

*A vibrating tuning fork on the mastoid stimulates the cochlea bilaterally; therefore, in this case, the left cochlea is stimulated by the Rinne test on the right (e.g., a false negative test). These tests are not valid, if the ear canals are obstructed with cerumen (e.g., will create conductive loss).

SYMBOLS USED WHILE PLOTTING THE AUDIOGRAM

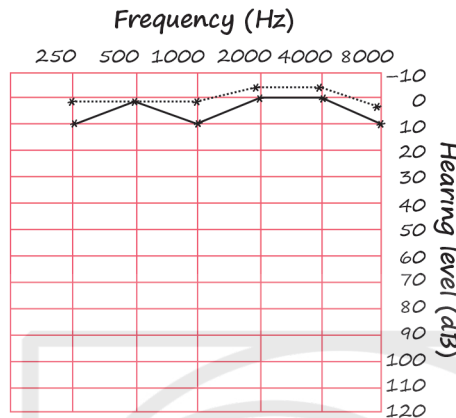
Condition	Symbol for right ear (In red)	Symbol for left ear (In blue)
AC unmasked	O	×
AC (Masked)	Δ	□
BC (Unmasked)	<	>
BC (Masked)	[]
Not-responding	○	+

Right ear is marked in Red and left ear in Blue (mnemonic R for R).

CBSPD
Dedicated to Education

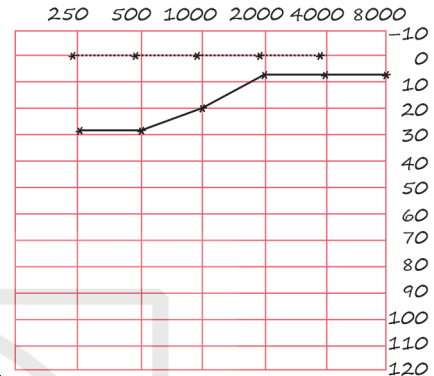
PURE TONE PATTERNS

Audiogram legend for a left ear
 X = AC unmasked
 > = BC masked
 □ = AC masked
] = BC masked



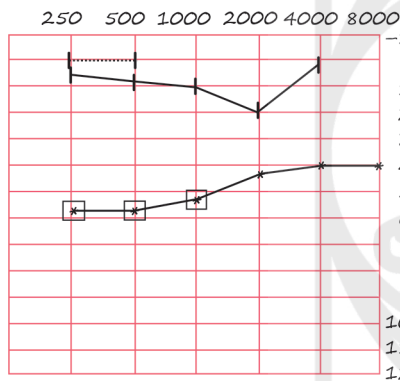
A

Normal audiogram



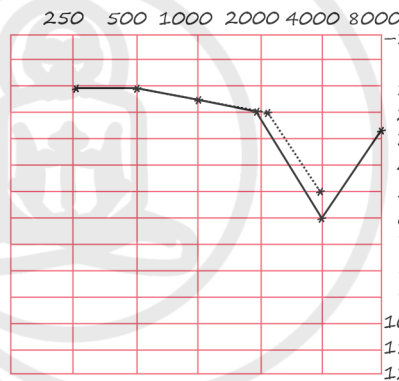
B

Conductive hearing loss (Otitis media)



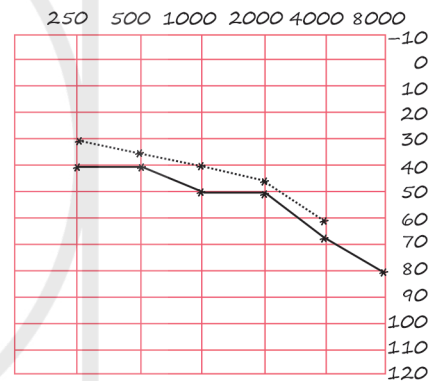
C

Conductive hearing loss (Otosclerosis)



D

Sensorineural hearing loss (Noise induced)



E

Sensorineural hearing loss (Presbycusis)

Conductive Hearing Loss (Figures B and C)

- Normal BC thresholds
- Increased AC thresholds
- Gap between AC and BC thresholds >10 dB (an air-bone gap)
- Usually lower tones affected
- Loss usually <60-70 dB
- Carhart's notch is present in BC threshold in Otosclerosis.

- Gap between AC and BC <10 dB (no air-bone gap)
- Dip at 4K is seen in noise-induced hearing loss
- Bilateral sloping (descending) curve is seen in Presbycusis.

Mixed Hearing Loss

- Both air and bone conduction thresholds below normal
- Gap between AC and BC thresholds >10 dB (an air-bone gap)

Sensorineural Hearing Loss (Figures D and E)

- Both air and bone conduction thresholds are raised



CBSPPD

Dedicated to Education

**PREVENTIVE AND
SOCIAL MEDICINE
(PSM)**

IMPORTANT INSTRUMENTS

Six's Maximum-Minimum Thermometer



- This thermometer has both mercury and alcohol.
- It measures the maximum and minimum air temperature reached over a period of time.
- A mercury-free variant of this thermometer is available.

Globe Thermometer




- It is used for the direct measurement of mean radiant temperature of the surroundings.
- It has a hollow metal bulb (6 inches diameter) which has a matte black paint which absorbs radiant heat. A specially calibrated mercury bulb thermometer is kept inside.
- The difference between the readings of the globe thermometer and bulb thermometer is the measure of the radiant heat.

Kata Thermometer



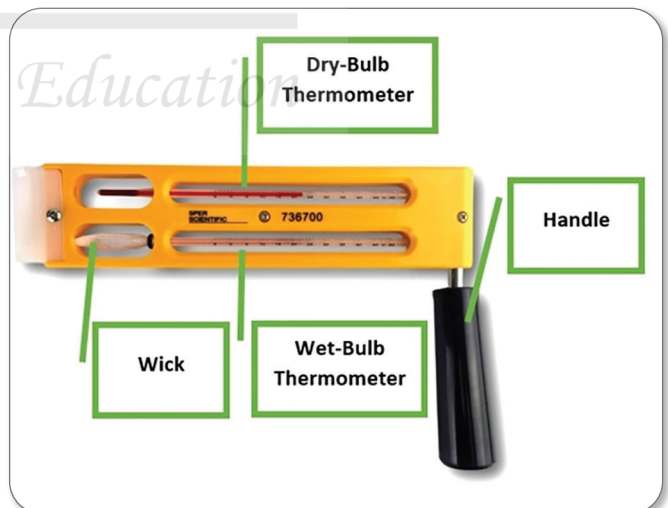
- It is an alcohol thermometer and consists of wet kata and a dry kata.
- A wet kata reading of 20 and above and dry kata reading of 6 and above were taken as indices of thermal comfort.
- It was originally used to measure the cooling power of air (air temperature, humidity and air movement) but currently it is used only as anemometer to measure low air velocities.

Sling Psychrometer







The image shown is of a sling psychrometer which is used to measure humidity.

Whirling Psychrometer






Used to measure the relative humidity.

HEALTH HAZARD SYMBOLS

Hazards	Symbols
Nonionizing radiation	 <ul style="list-style-type: none"> • It refers to any type of electromagnetic radiation that does not carry enough energy per quantum to ionize atoms or molecule. • Near ultraviolet, visible light, infrared, microwave, radio wave, and low-frequency (long wave) are all examples of non-ionizing radiation.
Ionizing radiation	 <ul style="list-style-type: none"> • The international radiation symbol (also known as trefoil) first appeared in 1946, at the University of California. • It is used for ionizing radiations, like X-ray, Gamma rays, etc.
Health hazard (serious)	
Health hazard (irritant)	

Contd...

Hazards	Symbols
Biohazard	 <ul style="list-style-type: none">• The symbol was developed in 1966 by Charles Baldwin.• It refers to biological substances that pose a threat to health of living organisms, primarily that of humans.• The term and its associated symbol is generally used as a warning, so that those potentially exposed to the substances will know to take precautions.• This can include medical waste or samples of a microorganism, virus or toxin.
Toxin/Poison	
Cytotoxic level	

Dedicated to Education

Contd...

SURAKSHA CLINICS

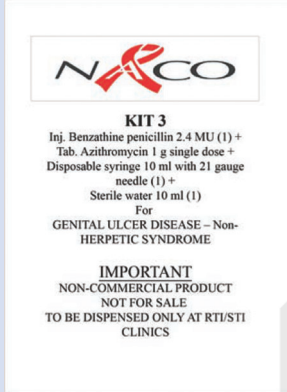

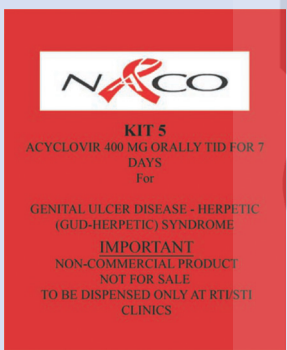



The Suraksha Clinics are for management of sexually transmitted diseases and patients are given color-coded kits.

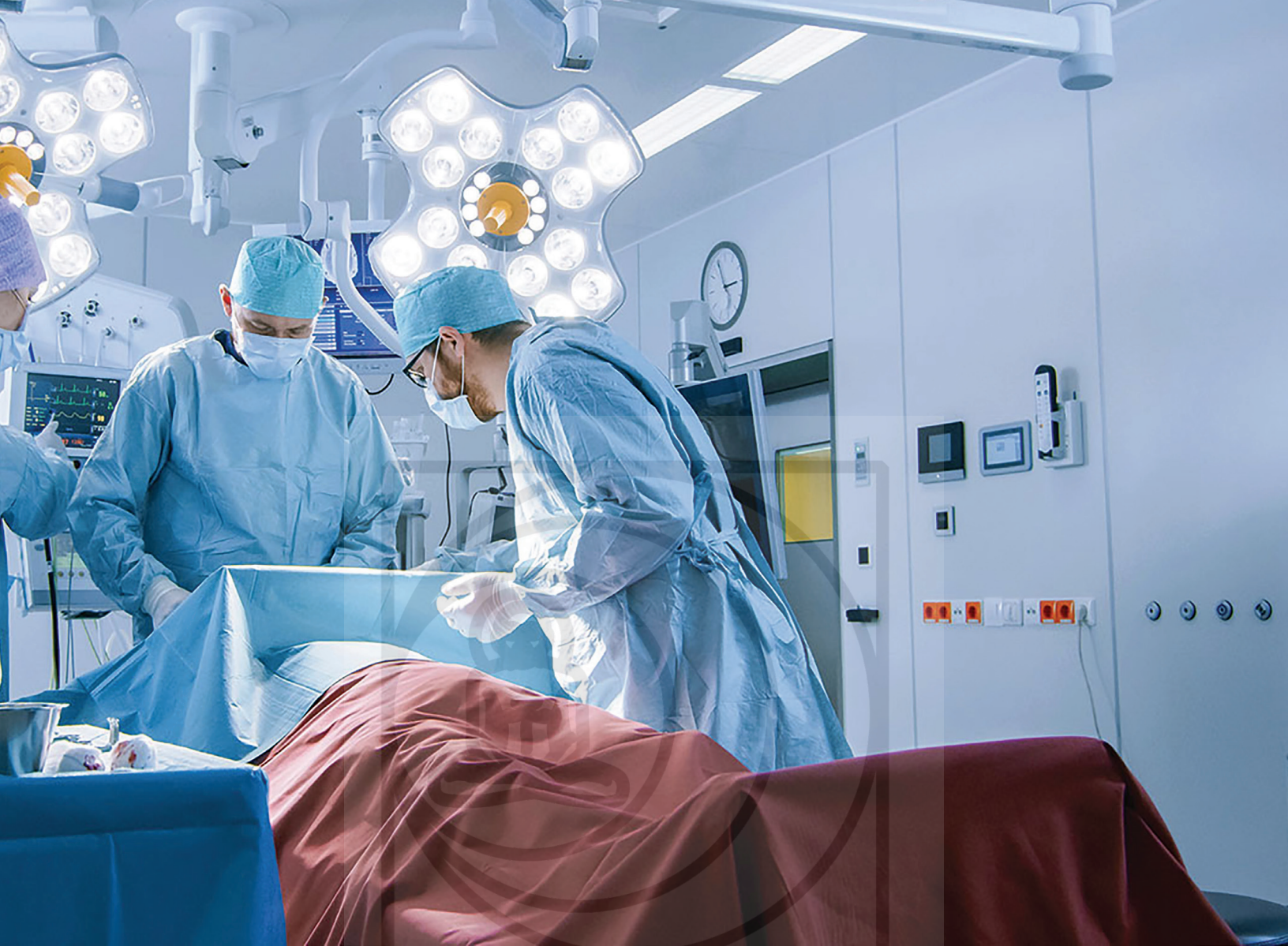Color-Coded Kits for Different Syndromic Manifestation in Suraksha Clinics

Kit No	Kit color	Clinical condition	Symptomology	Partner management	Pharmacotherapy
1	Gray 	Urethral discharge	<ul style="list-style-type: none"> • Urethral discharge (pus or mucopurulent) • Pain or burning while passing urine • Increased frequency of urination • Systemic symptoms like malaise, fever 	Treat all recent partners	Tab Azithromycin 1 g-OD stat + Tab Cefixime 400 mg OD stat
		Cervical discharge	<ul style="list-style-type: none"> • Nature and type of discharge (quantity, color and odor). • Burning while passing urine, increased frequency. • Genital complaints by sexual partners. • Low backache • (Take menstrual history to rule out pregnancy). 	Treat partners when symptomatic.	
		Painful scrotal swelling	<ul style="list-style-type: none"> • Swelling and pain in the scrotal region. • Pain or burning while passing urine. • Systemic symptoms, like malaise, fever. • History of urethral discharge. 	Treat all recent partners.	
2	Green 	Vaginal discharge (Vaginitis)	<ul style="list-style-type: none"> • Nature and type of discharge (quantity, color and odor). • Burning while passing urine, increased frequency. • Genital complaints by sexual partners. • Low backache • (Take menstrual history to rule out pregnancy). 	Treat partner when symptomatic.	Tab Secnidazole 2 g-OD stat + Cap. Fluconazole 150 mg OD stat

Contd...

Kit No	Kit color	Clinical condition	Symptomology	Partner management	Pharmacotherapy
3	White 	Genital ulcer (Non-herpetic)	<ul style="list-style-type: none"> Genital ulcer, single or multiple, painful or painless. Burning sensation in the genital area. Enlarged lymph nodes. 	Treat all sexual partners for past 3 months.	Inj. Benzathine penicillin (2.4 MU) - 1 vial + Tab Azithromycin (1g) - Single dose
4	Blue 	Genital ulcer disease (Non-herpetic) in patient allergic to penicillin			If allergic to inj. Penicillin: Doxycycline 100 mg (Bid for 15 days) + Azithromycin 1g (Single dose)
5	Red 	Genital ulcer disease	<ul style="list-style-type: none"> Genital ulcer or vesicles, single or multiple, painful, recurrent Burning sensation in the genital area 	No partner treatment	Tab. Acyclovir 400 mg TDS for 7 days
6	Yellow 	Lower abdominal pain (Pelvic inflammatory disease)	<ul style="list-style-type: none"> Lower abdominal pain Fever Vaginal discharge Menstrual irregularities, like heavy, irregular vaginal bleeding Dysmenorrhea dyspareunia Lower backache Cervical motion tenderness 	Treat 1 male partner with Kit-1	Tab. Cefixime 400 mg OD stat + Tab. Metronidazole 400 mg BD - 14 days + Doxycycline 100 mg BD - 14 days

Contd...



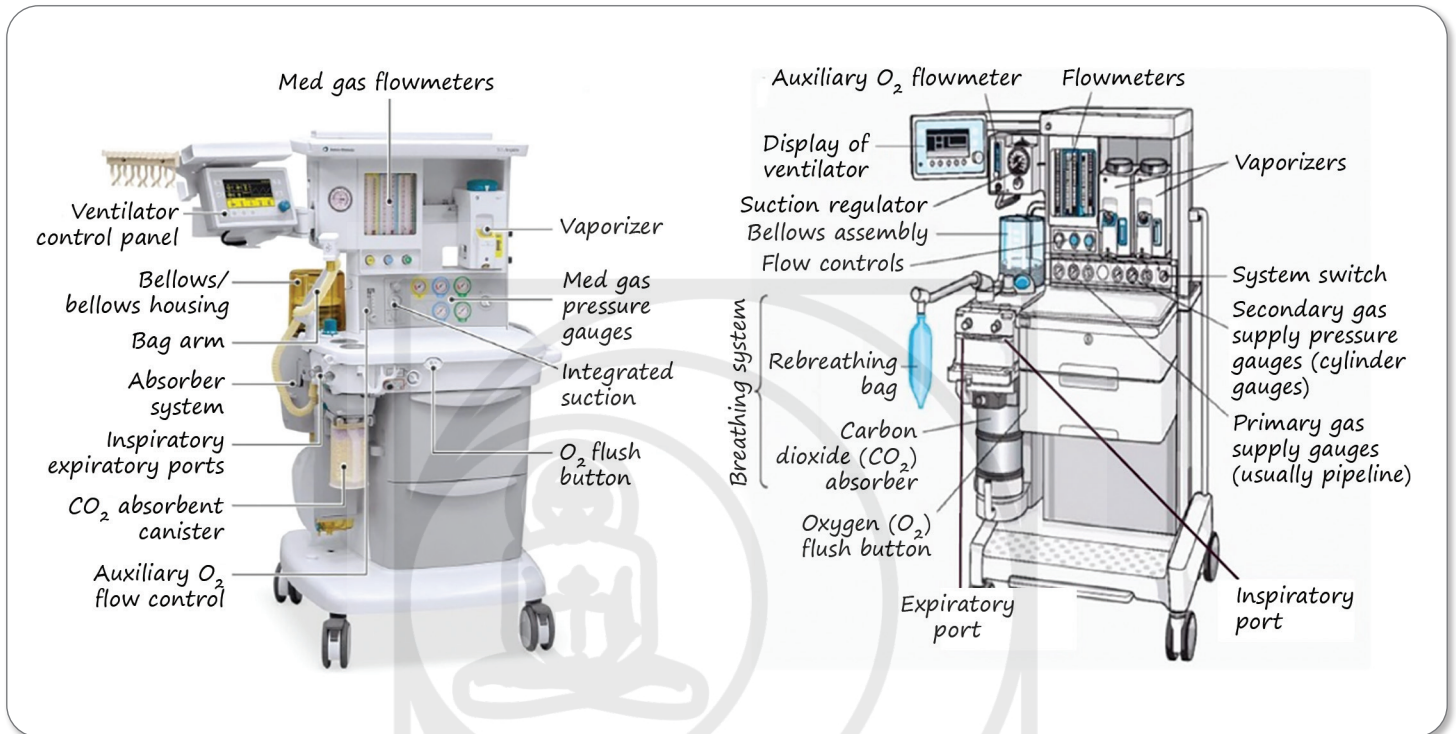
CBSPD

Dedicated to Education

ANESTHESIA

ANESTHESIA MACHINE

Anesthesia Workstation: Boyle's Machine



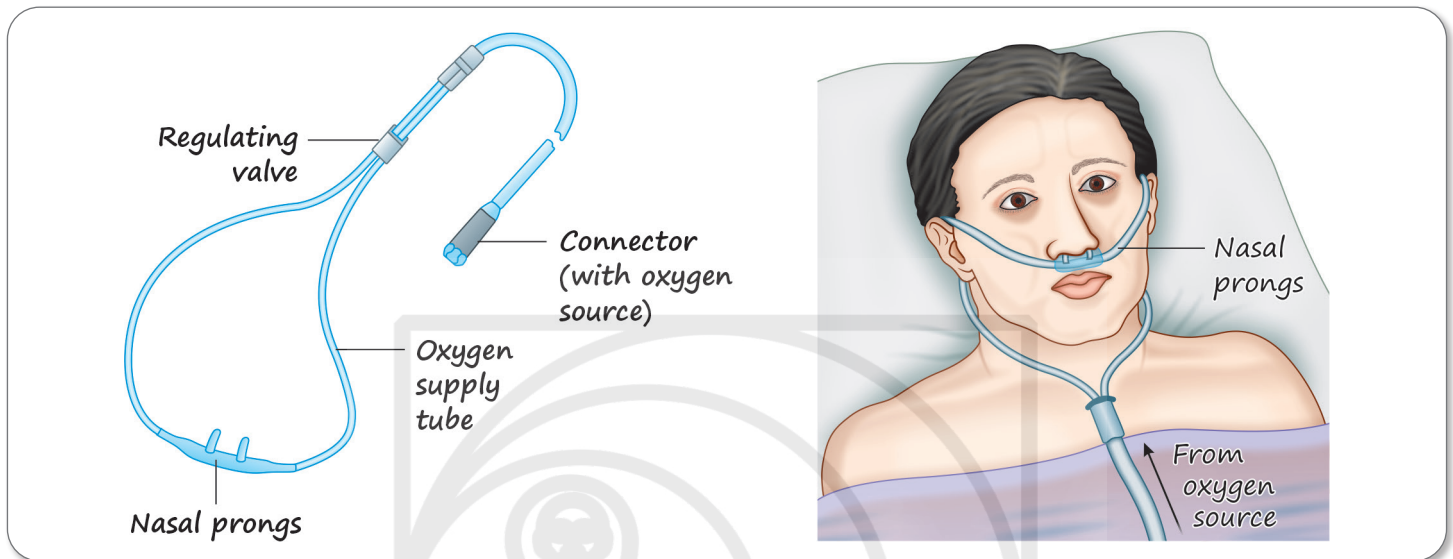
- The prototype of this device is the Boyle's machine which was first invented by Edmund Gaskin Boyle in 1917.
- The Boyle's machine used to provide anesthesia has evolved over the years into anesthetic workstations that are currently being used.

CBSPD

Dedicated to Education

OXYGEN THERAPY

Nasal Cannula



Nasal cannula

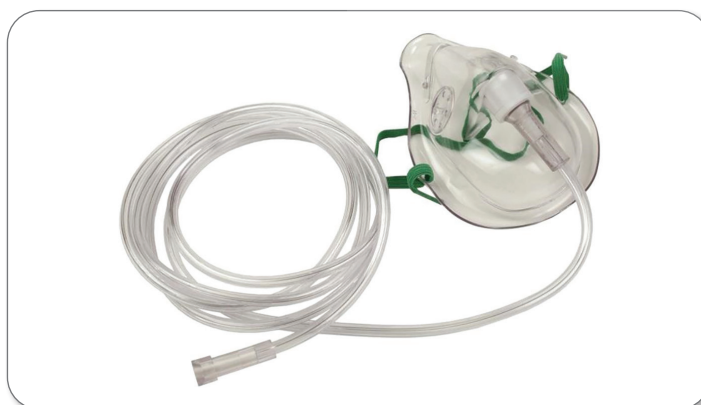
- Consists of two soft prongs attached to O_2 supply tubing.
- $FiO_2 = 20\% + (4 \times \text{oxygen liters flow})$
- No increase in FiO_2 , if flow is more than 6 L/min.
- Nasopharynx acts as a reservoir. A flow rate of 2-6 L/min delivers FiO_2 of 0.28-0.45 respectively.
- Transparent mask that is provided with side holes
- Reservoir capacity is 100-250 ml
- Different oxygen flow rates result in high variables and unpredictable FiO_2 .
- To prevent rebreathing of expiratory gases, we need to keep flow rate of oxygen 6 L/min.
- Flow rate greater than 8 L/min does not increase FiO_2 much.

Advantages	Disadvantages
<ul style="list-style-type: none"> • Ideal for patient on long-term oxygen therapy. • Light weight and comfortable • The patient is able to eat, speak and drink 	<ul style="list-style-type: none"> • Cannot provide high flow O_2 • Irritation and crusting of nasal mucosa • FiO_2 varies with respiratory effort

Disadvantages

- Uncomfortable
- Does not deliver constant FiO_2
- Interference with communication
- Chances of rebreathing

Simple Face Mask



Simple face mask

Partial Rebreathing Mask

- Mask with reservoir bag of capacity 1 liter.
- Oxygen flows directly into the reservoir bag, which fills during exhalation.
- It is designed in such a way that it captures exhaled gases from initial parts of expiration from the dead spaces.
- Useful in situation where supplies are limited.
- Deliver FiO_2 , between 0.6 and 0.8.
- A minimum of 8 L/min should enter the mask to remove exhaled CO_2 , and to refill oxygen reservoir. Flow rate must be sufficient to keep bag 1/3 to 1/2 inflated.

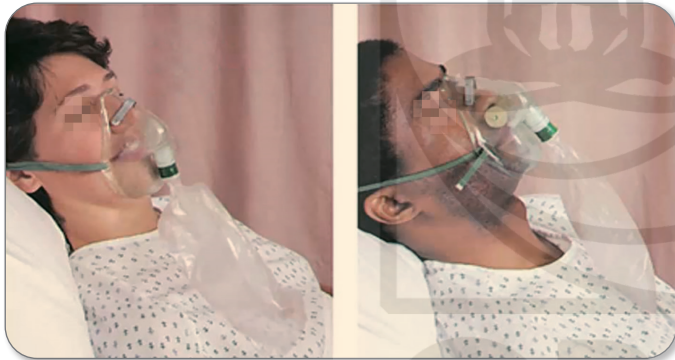Advantages	Disadvantages
Inspired gas not mixed with room air	Same as for face mask

Non-Rebreathing Mask

- Provided with one-way valve between mask and bag, exhalation ports.
- FiO_2 of 95% can be achieved with an oxygen flow rate of 10-15 L/min.
- Higher oxygen supply rate is required.
- Desirable in cases where rebreathing of CO_2 , would be detrimental, for example, after head injury.
- Best results will be achieved by adequate flow rates such that reservoir bag empties by no more than a third.

Advantages

- Highest possible FiO_2 without intubation
- Suitable for spontaneously breathing patients with severe hypoxia.



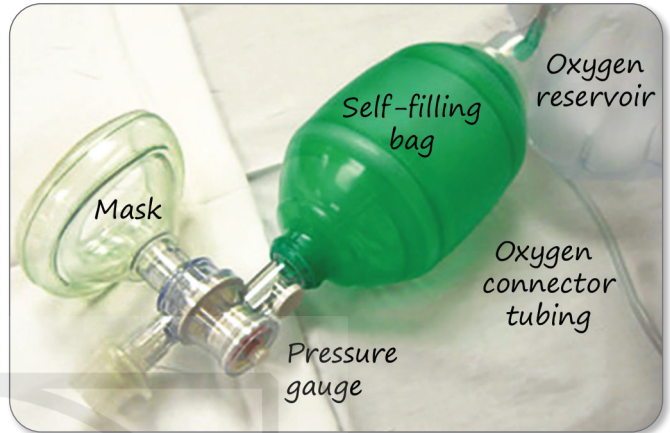
Partial rebreathing mask Vs Non-Rebreathing mask

Points to Remember

Summary of low flow devices


Devices and flow rate (L/min)	FiO_2 achieved
Nasal cannula (1-6 L/min)	0.24-0.45
Oxygen mask (6-8 L/min)	0.44-0.60
Mask with reservoir bag (6-10 L/min)	0.6-0.8
Mask with non-rebreathing reservoir bag (6-10 L/min)	0.6-0.9

Self-Limiting Bag

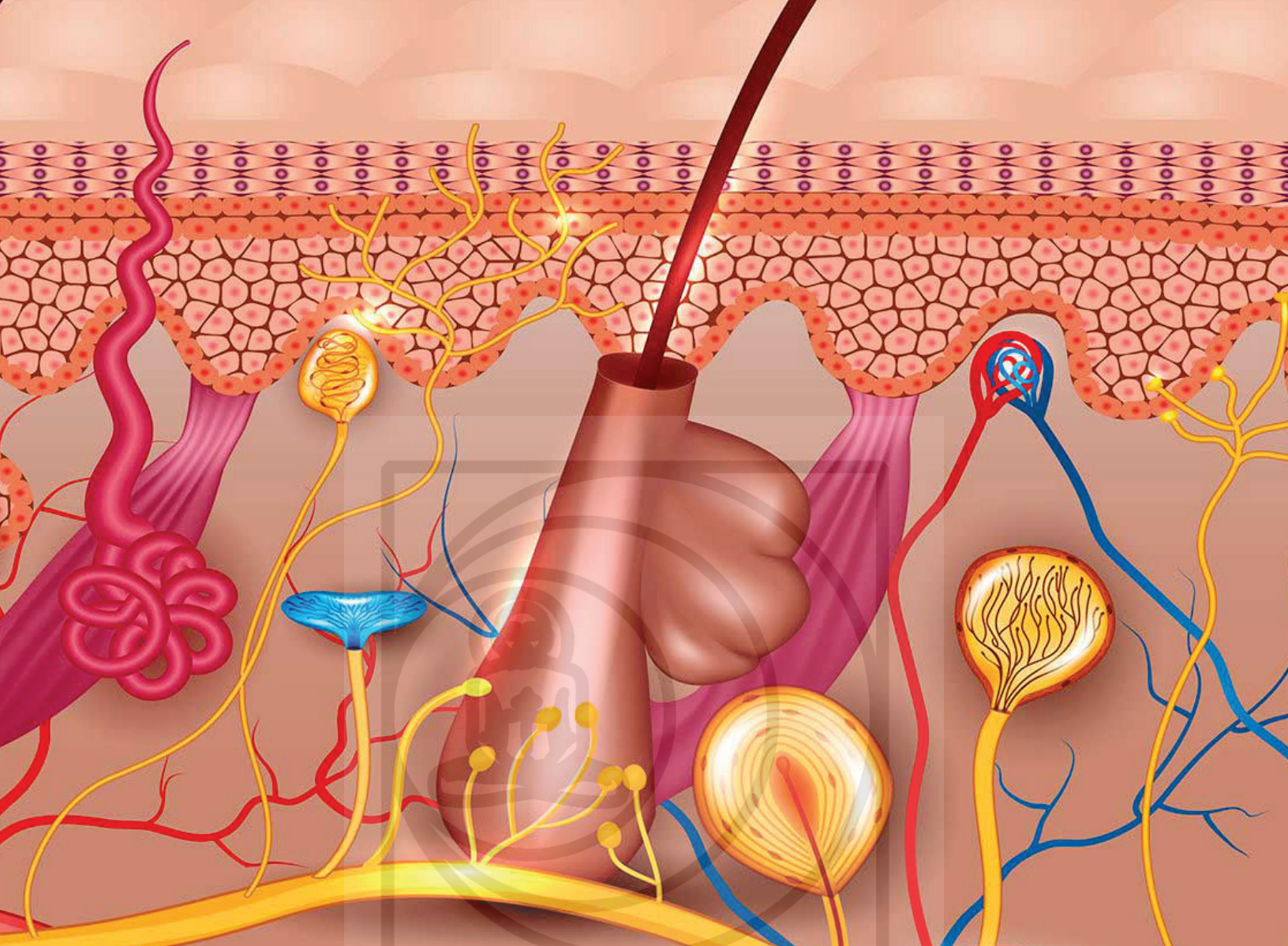


- It is easy to use as it reinflates completely without any external compressed source of gas.
- The disadvantage of such bag is that it cannot be used to administer free-flow of oxygen.
- The self-inflating bag usually has an attached oxygen reservoir bag, it delivers 90-100% oxygen and without reservoir bag, it delivers only 40-50% oxygen.

Flow Inflating Bag



- Delivers free flow of oxygen, fills only when gas from a compressed source flows into it.
- Since it does not have a safety pop-off valve, it requires pressure gauge for monitoring.

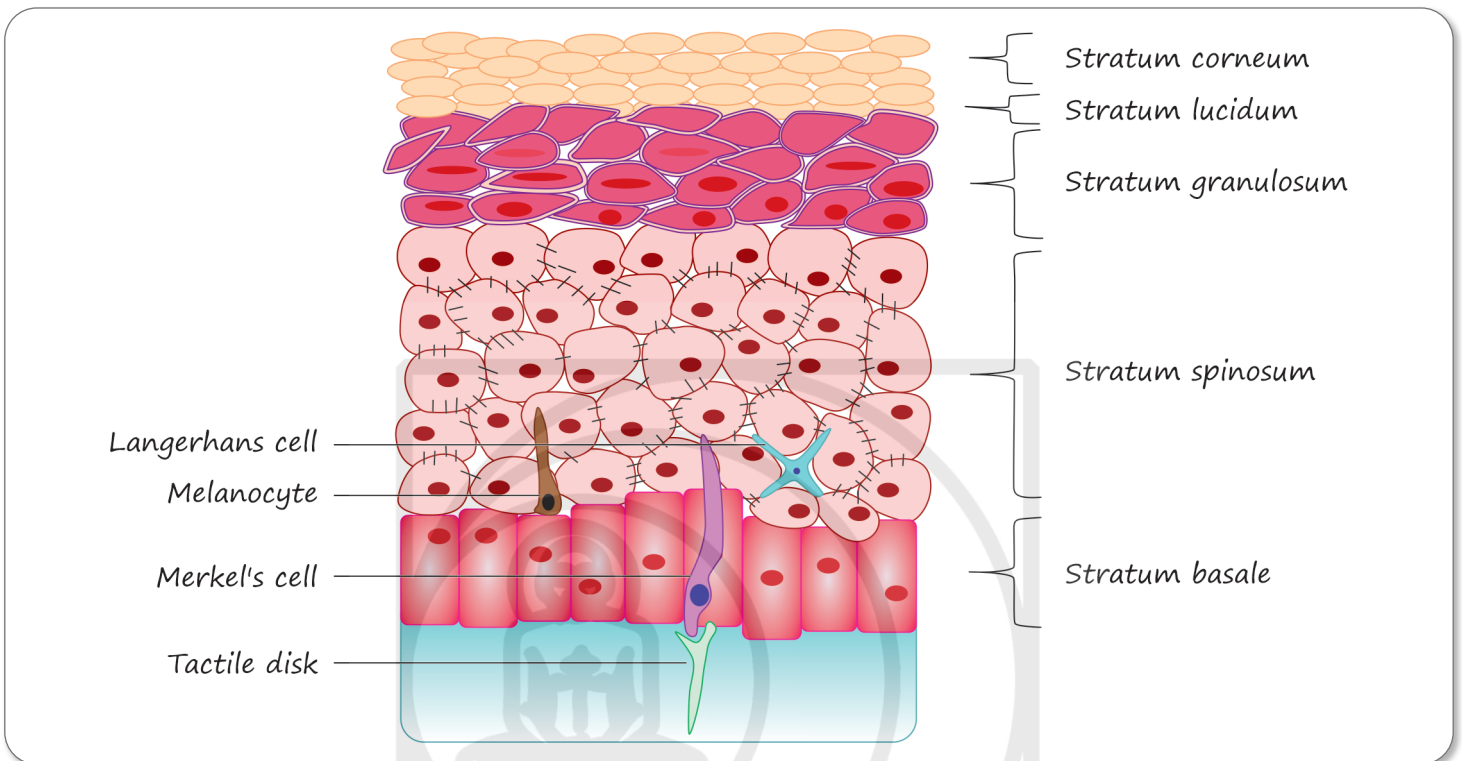


CBSPD

Dedicated to Education

DERMATOLOGY

LAYERS AND CELLS OF EPIDERMIS



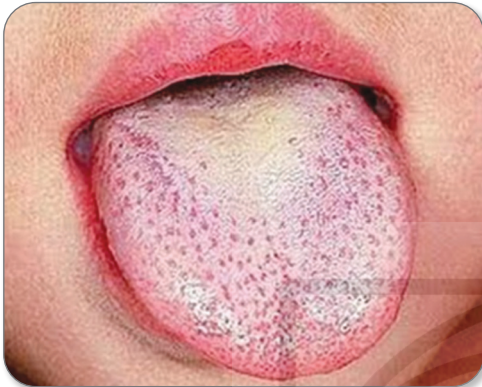Layer	Description
Stratum corneum	Flat, dead, scale-like cells filled with keratin. Continually shed.
Stratum lucidum	Clear layer—present in thick skin only.
Stratum granulosum	Cells form links with neighbors.
Stratum spinosum	Squamous cells begin keratin synthesis. Thickest layer of epidermis.
Stratum germinativum	The basement membrane—single layer of columnar epithelial cells. Gives rise to keratinocytes. Contains melanocytes.

- Keratinocytes are the predominant cells (constituting around 90%) of epidermis. It is the barrier against environmental damage, once pathogens start invasion, they produce

- proinflammatory mediators (chemokines—CXCL-10 and CCL-2 which attract leukocytes).
- Melanocytes and Merkel's cells are also in basal layer (ruled out).
- **Melanocytes** are dendritic cells present in stratum basale. Derived from neural crest. They synthesize melanosomes (melanin containing cell organelles) which are transferred to adjacent keratinocytes via dendrites.
- **Merkel's cells/tactile epithelial cells/Haarscheibe cells:** They present in stratum basale, contain desmosomes (like keratinocytes). They are type 1, slow adapting touch receptors so also commonly known as touch cells.
- Langerhans cells are mainly present in stratum spinosum layer and derived from bone marrow. So, answer is Langerhans cells.
- Langerhans cells have characteristic (Hallmark) rod or tennis racket-shaped intracellular organelles known as Birbeck granules (which help in receptor-mediated endocytosis).
- Langerhans cells express markers like CD217 (langerin), CD1a and S100.

TONGUE FINDINGS IN DIFFERENT DISEASES

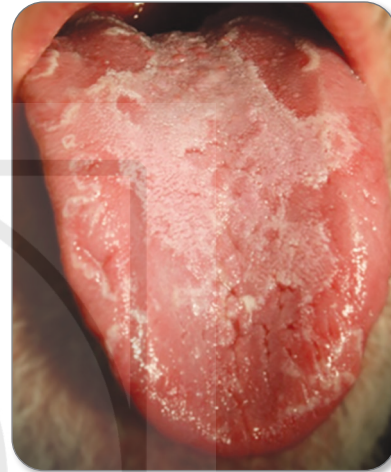Strawberry Tongue



- Strawberry tongue/Raspberry tongue refers to glossitis which manifests with hyperplastic (enlarged) fungiform papillae, giving the appearance of a strawberry.
- Strawberry tongue seen in Kawasaki disease.

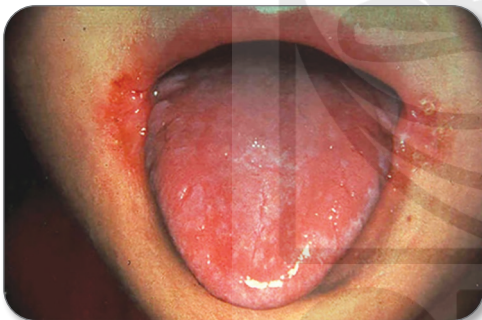
tiny projections that contain taste buds (papillae). Potential causes include broad-spectrum antibiotic and tobacco use.

Geographic Tongue/Benign Migratory Glossitis



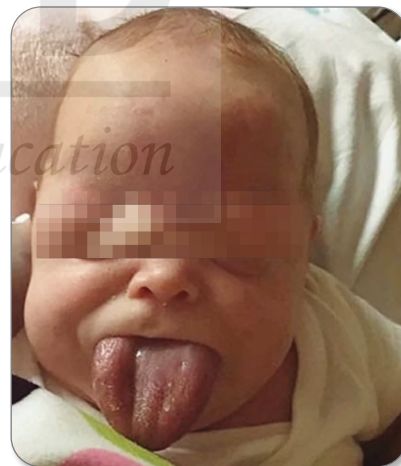- It is characterized by areas of atrophy and depapillation (loss of papillae), leaving an erythematous (darker red) and smoother surface than the unaffected areas.
- The depapillated areas are usually well demarcated and bordered by a slightly raised, white, yellow or gray, serpiginous (snaking) peripheral zone.
- Geographic tongue is also more common in people who have psoriasis or cracks and grooves on the top and sides of their tongue (fissured tongue).

Magenta Tongue



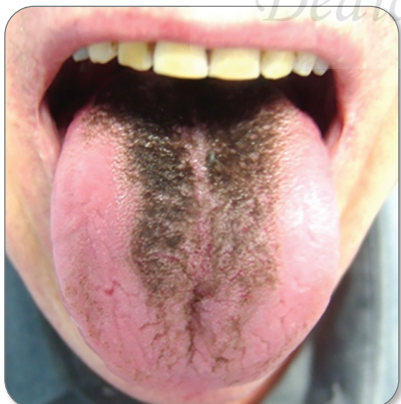Purplish-red discoloration of the tongue, with edema and flattening of the filiform papillae on the dorsum of the tongue. It occurs due to vitamin B₂ (riboflavin) deficiency.

Macroglossia

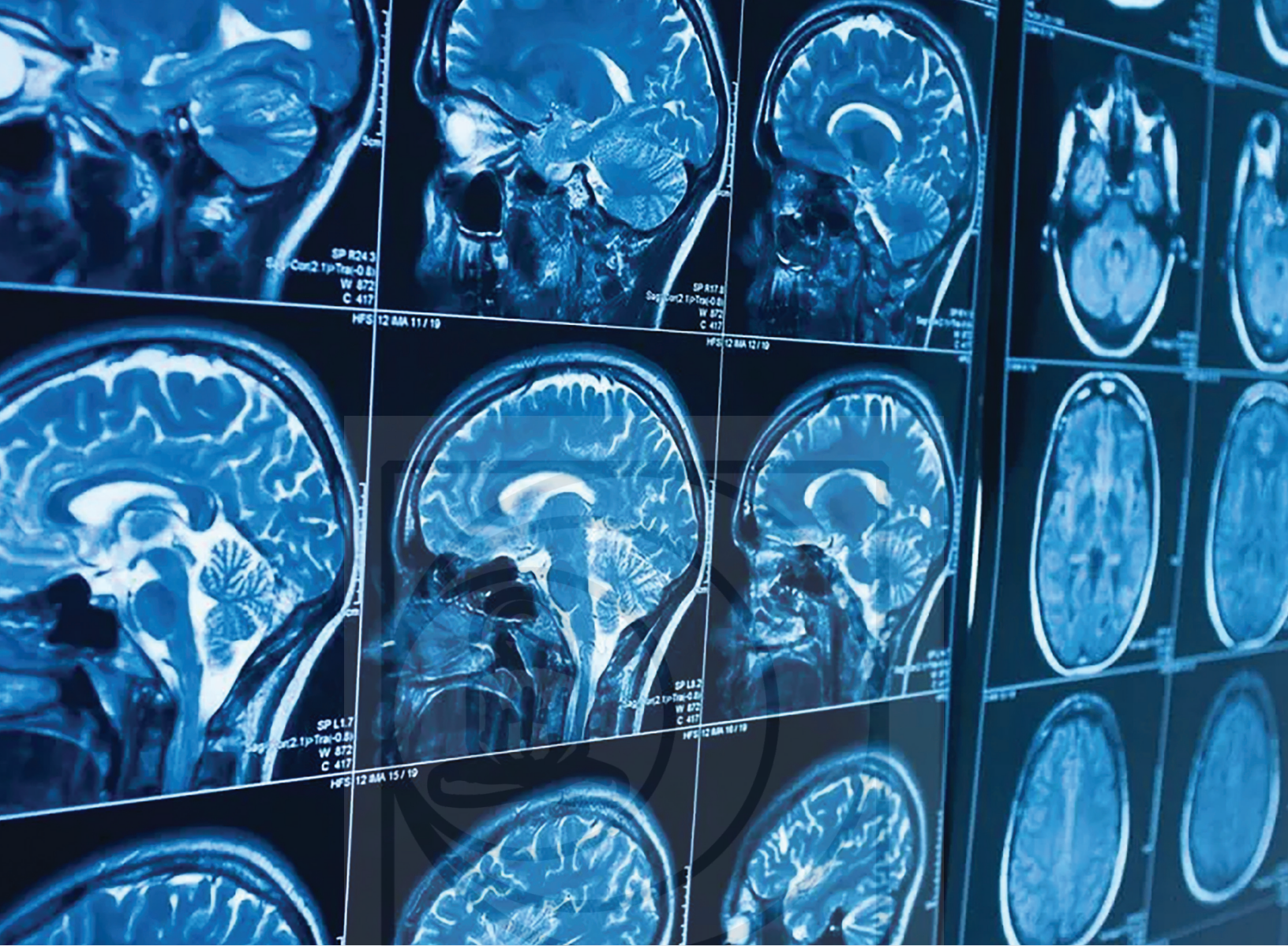

Macroglossia may occur secondary to a primary disorder that may be either congenital (e.g., Down syndrome or Beckwith-Wiedemann syndrome, primary amyloidosis, and congenital hypothyroidism) or acquired (e.g., as a result of trauma or malignancy).

Black Hairy Tongue



Black hairy tongue is a harmless condition. It is caused by a build-up of dead skin cells on the



CBSPD

Dedicated to Education

RADIOLOGY

FOCUSED ASSESSMENT WITH SONOGRAPHY IN TRAUMA (FAST)

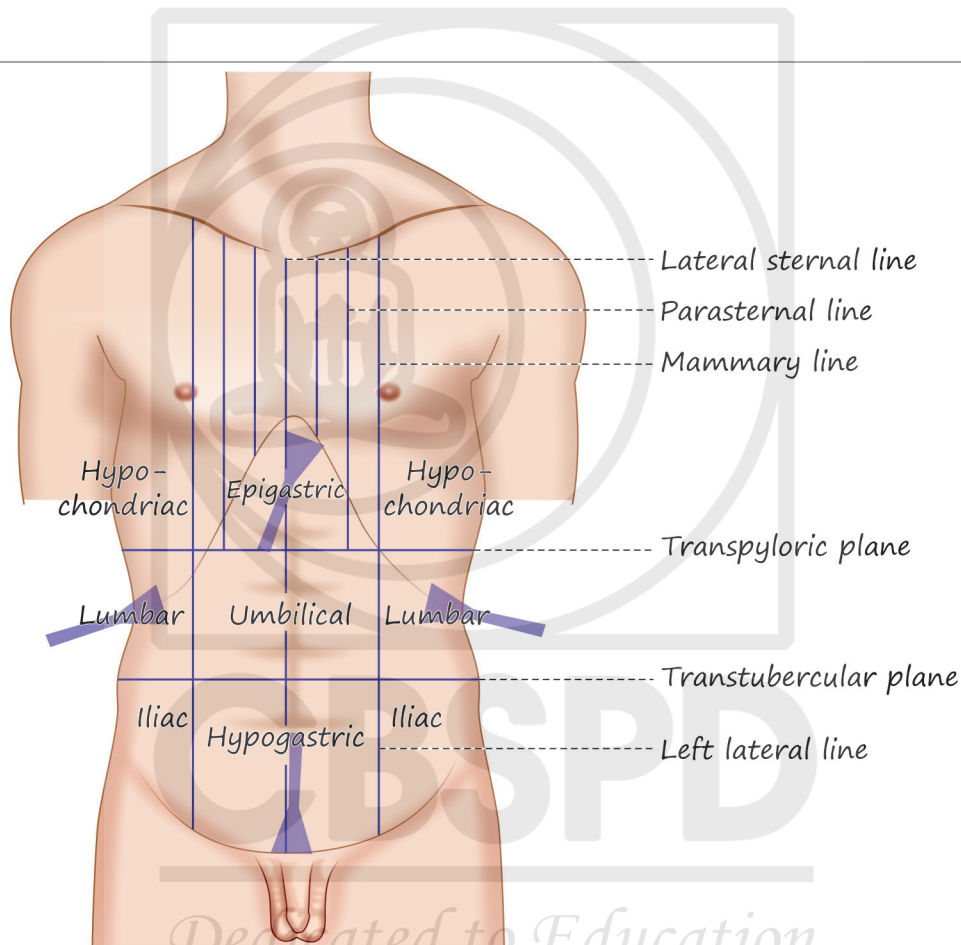
- Performed by the trauma surgeon at the bedside.
- **Aim:** To identify the presence of free fluid (hemoperitoneum) which is an important factor that decides further surgical versus non-surgical management.

Entrance Corner

Role of Imaging in Abdominal Trauma

- FAST: Screening for free fluid/hemoperitoneum
- CE-CT Abdomen is investigation of choice.

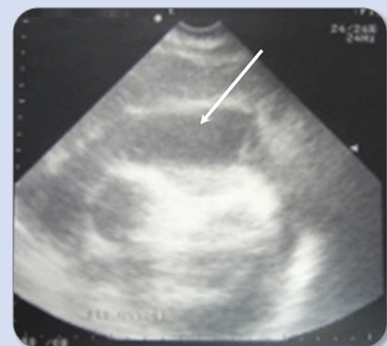Interpretation



FAST Protocol

Subxiphoid transverse view

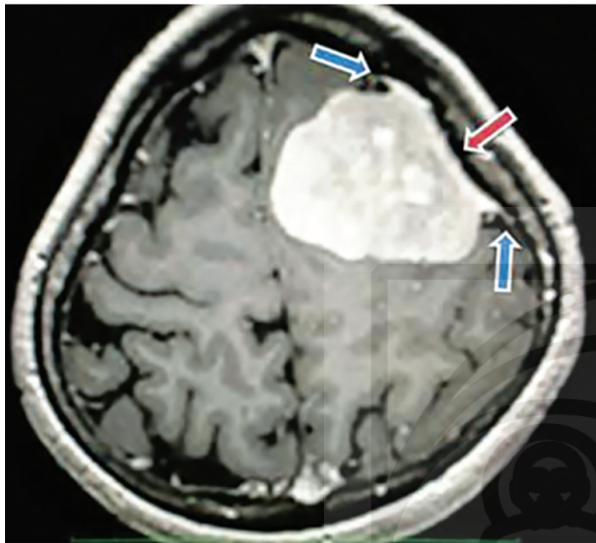
- To assess for pericardial effusion and left lobe liver injuries.
- Pericardial effusions can be detected by identifying an anechoic stripe between the epicardium and the pericardium.
- The subxiphoid view allows for imaging of all chambers of the heart and the pericardium.
- The subxiphoid image shown demonstrates a traumatic tamponade (arrow) overlying the heart, leading to collapse of the right ventricle.



Contd...

CENTRAL NERVOUS SYSTEM IMAGING

Dural Tail Sign

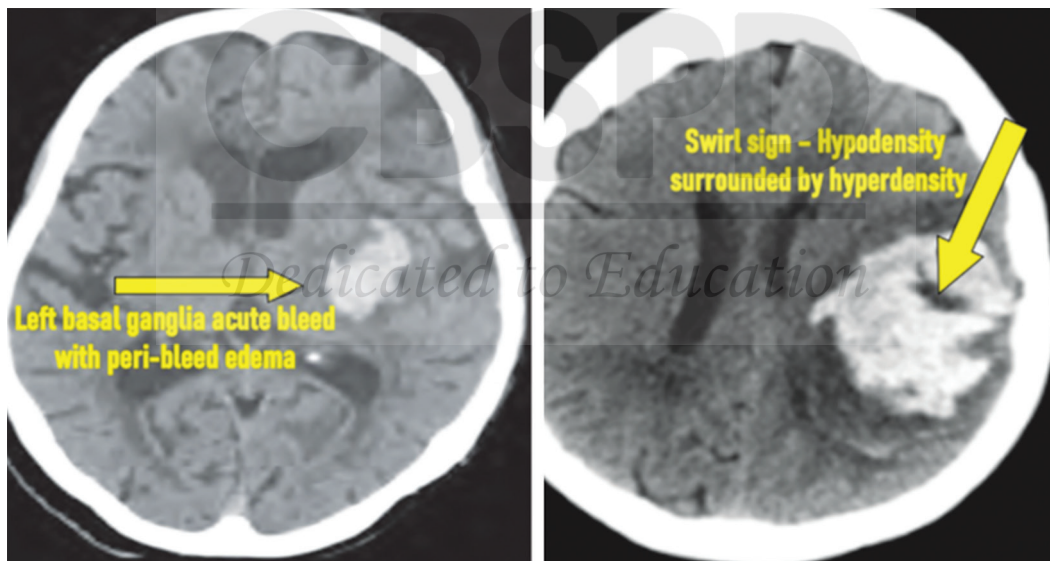


This refers to the enhancement of the dural lining adjacent to mass on contrast-enhanced MRI Brain. A dural tail is an MRI finding that strongly suggests that the lesion is a meningioma. Studies suggest that the actual "tail" is due to dural hypertrophy, rather than tapering of the actual meningioma. It is not specific for meningiomas and is also seen in Pleomorphic xanthoastrocytoma, Glioblastoma and other dural-based lesions.

Meningioma

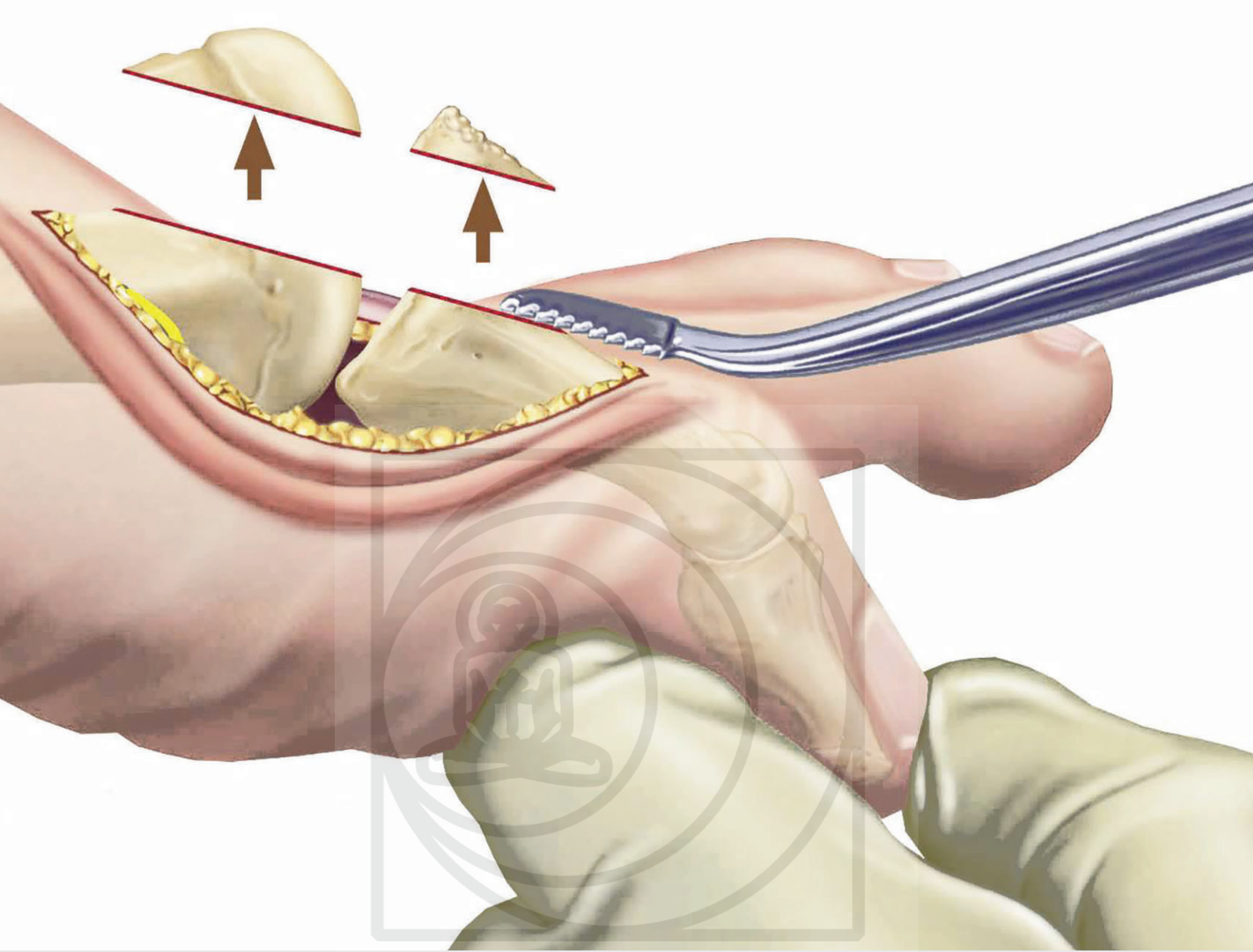
- Mother-in-law sign on angiography: The mother in law sign is perhaps uncharitably (depends on the mother in law I suppose) used to describe lesions that enhance early during the arterial phase and remain opacified well after the venous phase. The joke is that a mother in law comes early and stays late.
- Sun-burst/Spoke-wheel pattern of vessels on angiography.

Hemorrhagic Stroke: Acute Hemorrhage Appears Hyperdense on CT



MRI Appearance of bleed:

- Best sequence for detection of bleed on MRI is Gradient echo (GRE) and Susceptibility weighted imaging (SWI) sequences. SWI is much more sensitive than GRE.
- Appearance on T1W/T2W sequences is variable according to the age of the bleed/hemoglobin breakdown products present. The following sequence is usually followed:



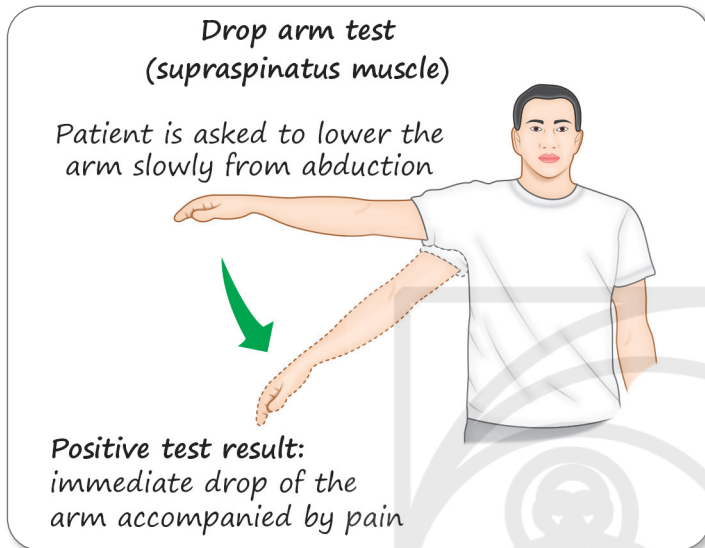
CBSPD

Dedicated to Education

ORTHOPEDICS

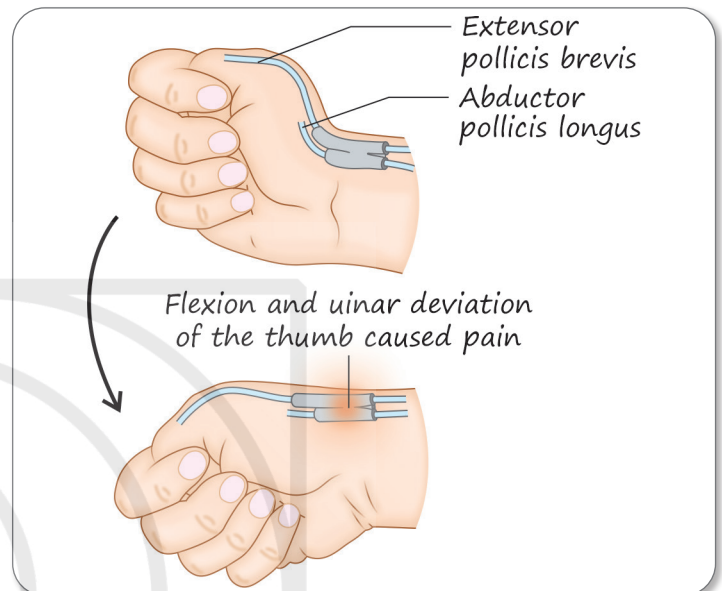
CLINICAL TESTS IN ORTHOPEDICS

Drop Arm Test:



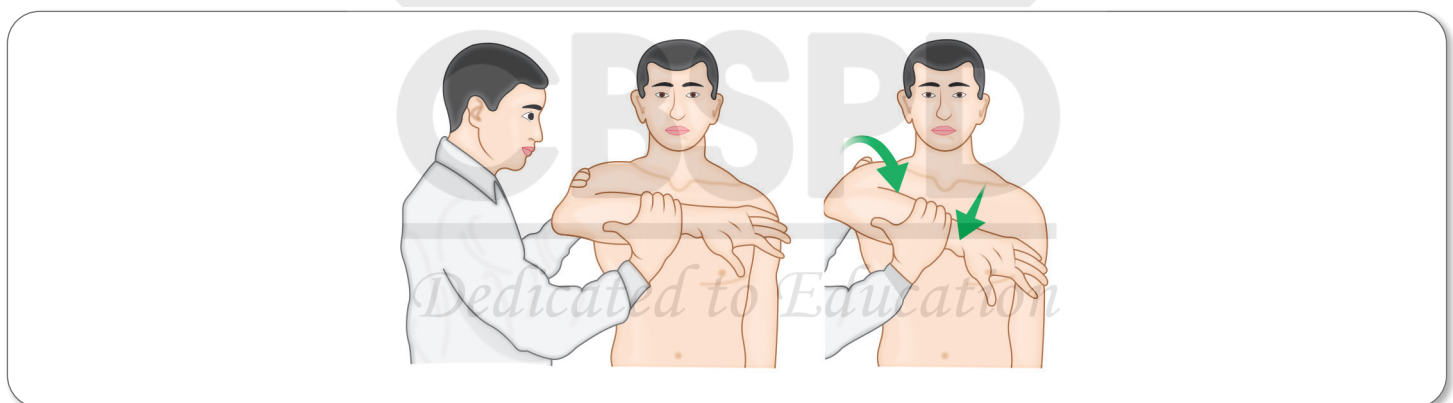
- Ask the patient to raise his/her arm on the side to shoulder level and then to slowly lower the arm.
- If the patient has trouble holding the arm abducted at shoulder level, the test is positive and is consistent with a rotator cuff tear.

Finkelstein Test:



- Instruct the patient to make a fist with thumb down across the palm.
- Introduction of ulnar deviation results in pain in patients with De Quervain tenosynovitis.

Hawkin's Test:



- Place elbow and the shoulder at 90° with one hand grasping the elbow and the other grasping the wrist in sitting or standing position.
- Introduce internal rotation at the shoulder to look for pain with ROM, which indicates pathology of the rotator cuff muscle group or the long head of the biceps tendon.



CBSPD

Dedicated to Education

PSYCHIATRY

IMPORTANT DATES IN PSYCHIATRY

World Mental Health Day: 10 October



World Bipolar Day: 30 March



World Down Syndrome Day: 21 March

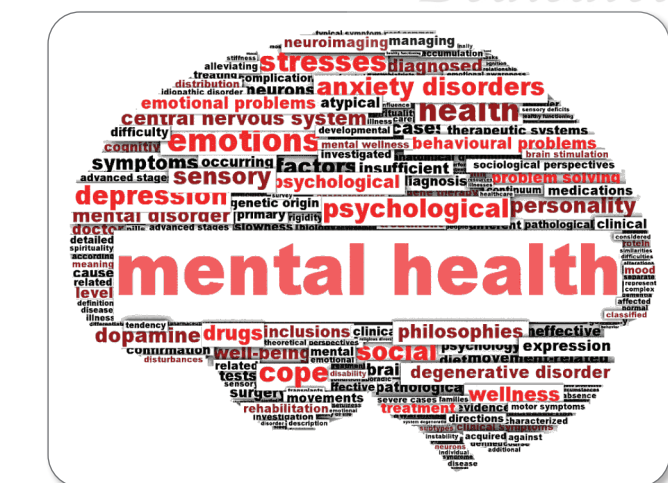


World Autism Awareness Day: 2 April



World Autism Awareness Day is observed on 2 April to educate people about autism and spread kindness.

Mental Retardation Awareness Month: 1-31 March



World No Tobacco Day: 31 May



Note:

- World Schizophrenia Day: 24 May
- National Mental Health Awareness Day: 06 August

MINI-MENTAL STATE EXAMINATION/FOLSTEIN TEST

Mini-Mental State Examination (MMSE)

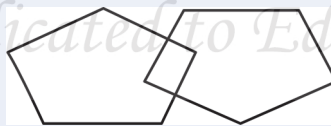
Patient's Name: _____ Date: _____

Instruction: Score one point for each correct response within each question or activity.

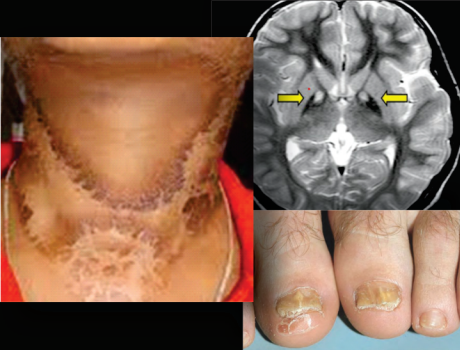Maximum score	Patient's score	Questions
5		"What is the year? Season? Date? Day? Month?"
5		"Where are we now? State? County? Town/city? Hospital? Floor?"
3		The examiner names three unrelated objects clearly and slowly, then the instructor asks the patient to name all three of them. The patient's response is used for scoring. The examiner repeats them until patient learns all of them, if possible.
5		"I would like you to count backward from 100 by sevens." (93, 86, 79, 72, 65,...) Alternative: "Spell WORLD backwards." (D-L-R-O-W)
3		"Earlier I told you the names of three things. Can you tell me what those were?"
2		Show the patient two simple objects, such as a wristwatch and a pencil, and ask the patient to name them.
1		Repeat the phrase: No ifs, ands, or buts."
3		"Take the paper in your right hand, fold it in half, and put it on the floor." (The examiner gives the patient a piece of blank paper.)
1		Please read this and do what it says." (Written instruction is "Close your eyes.")
1		"Make up and write a sentence about anything." (This sentence must contain a noun and a verb.)
1		Please copy this picture." (The examiner gives the patient a blank piece of paper and asks him/her to draw the symbol below. All 10 angles must be present and two must intersect.)
30		Total



Dedicated to Education



- Mini-Mental State Examination (MMSE, also known as Folstein test) is a score out of 30 and is used to measure cognitive impairment.
- A score of less than 24 is considered impaired cognition.
- A score of less than 24 on the MMSE is 85% sensitive and 90% specific for dementia.
- The areas tested are included in the following table:



ONE Touch Picture Recap

Subjects Covered

ENT • Preventive and Social Medicine (PSM) • Orthopedics • Medicine • Surgery
• Pediatrics • Obstetrics & Gynecology • Ophthalmology • Anesthesia
• Dermatology • Radiology • Psychiatry

Salient Features

Bard-Parker Handle



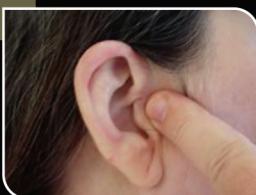
- Flat stainless steel instrument with one end narrower with a slot on either side for attaching the scalpel blade.
- A number is written on the handle. The numbers may be 3, 5, 7 and 4.

Comprehensive Topic Coverage: All significant previous year topics are systematically organized within the book, streamlining your study process and ensuring that essential knowledge is readily accessible.

Gestational age

<28 weeks
28-32 weeks
32-34 weeks
>34 weeks

High Yield Tables: Frequently asked Topics and clinical correlations are tabulated for easy learning and more visual impact for long-term memory.

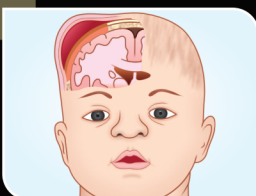


Extensive Image Database: It includes an impressive collection of **1600+** images, enriching your understanding and retention of crucial medical concepts.

Points to Remember

- Endotracheal Tube-Difference from Standard ETT**
- The distinctive feature is a metal wire coil embedded in the wall of the tube shaft. The fact that these tubes contain a metal wire coil means there is no need for a radiopaque line.
 - In contrast to "standard" ETT tubes, the tube connector of armored tubes is firmly fixed to the tube shaft and is not detachable.
 - A further difference is that armored tubes are bendier and therefore, not as well performed as standard tubes. Because of this they are more likely to require a stylet for successful intubation.
 - The benefit of armored ETT over normal ETT is that it is bend resistant.

Points to Remember: Must know facts covered extensively throughout the Book



Effective Pictorial Illustrations: The book employs high-quality pictorial illustrations to simplify the intricate medical subjects, aiding in better comprehension and recall.

Modified Well's Criteria for Predicting Deep Vein Thrombosis

Variable	Score
Lower limb injury/Surgery/immobilization in plasters	1
Bedridden >> days or Surgery in last 4 weeks*	1
Tender along femoral or popliteal vein	1
Swollen entire limb	1
Calf diameter >> cm of opposite calf at ± 0 cm below tibial tuberosity	1
Pitting edema	1

Centralized Clinical Information: Consolidates essential scores, classifications, grades, and stages for surgery, medicine, pediatrics, making it a valuable reference for key clinical information.



CBS Publishers & Distributors Pvt. Ltd.

4819/XI, Prahlad Street, 24 Ansari Road, Daryaganj, New Delhi 110 002, India

E-mail: feedback@cbspd.com, Website: www.cbspd.com

New Delhi | Bengaluru | Chennai | Kochi | Kolkata | Lucknow | Mumbai

Hyderabad | Jharkhand | Nagpur | Patna | Pune | Uttarakhand

ISBN: 978-93-90619-50-4

