

Practical Manual of Histology

Second Edition

As per the latest CBME Guidelines | Competency Based Undergraduate Curriculum for the Indian Medical Graduate

is the thoroughly rewritten, revised and updated edition of the book, restructured in accordance with the CBME Guidelines | Competency Based Undergraduate Curriculum for the Indian Medical Graduate recommended by the National Medical Commission. It covers all the competencies of histology.

This book is written in a very simple style and an easy to understand language. It is a complete guide for the learners as well as the teachers. The hand-drawn diagrams given for each tissue are its unique feature. The specific learning objectives are given in the beginning of each chapter and guide a novice student as to what he/ she is required to know on the topic. This book encompasses all the important points of the normal microanatomy of human tissue. It is complete in itself and, if studied alone, can help the student secure hundred percent marks in histology MCQ-based questions of all the examinations including NEXT, UPSC, USMLE, PLAB, FMGE, etc.

Hina Sharma MBBS, MD (Anatomy)

is presently Associate Professor, Department of Anatomy, Geetanjali Medical College and Hospital (GMCH), Udaipur, Rajasthan. She obtained her MBBS degree from King George's Medical College, Lucknow, UP, and MD (Anatomy) from GMCH, Udaipur. She completed 'Advanced Course in Medical Education' from NHL Municipal Medical College, Ahmedabad. Her keen interest in teaching and making learning easier for students has led to the script of this book.



CBS Publishers & Distributors Pvt Ltd
4819/XI, Prahlad Street, 24 Ansari Road, Daryaganj, New Delhi 110 002, India
E-mail: delhi@cbspd.com, cbspubs@airtelmail.in; Website: www.cbspd.com
New Delhi | Bengaluru | Chennai | Kochi | Kolkata | Lucknow | Mumbai
Hyderabad | Jharkhand | Nagpur | Patna | Pune | Uttarakhand



QR code to access online CBS Catalogue

ISBN: 978-93-5466-374-1



Sharma



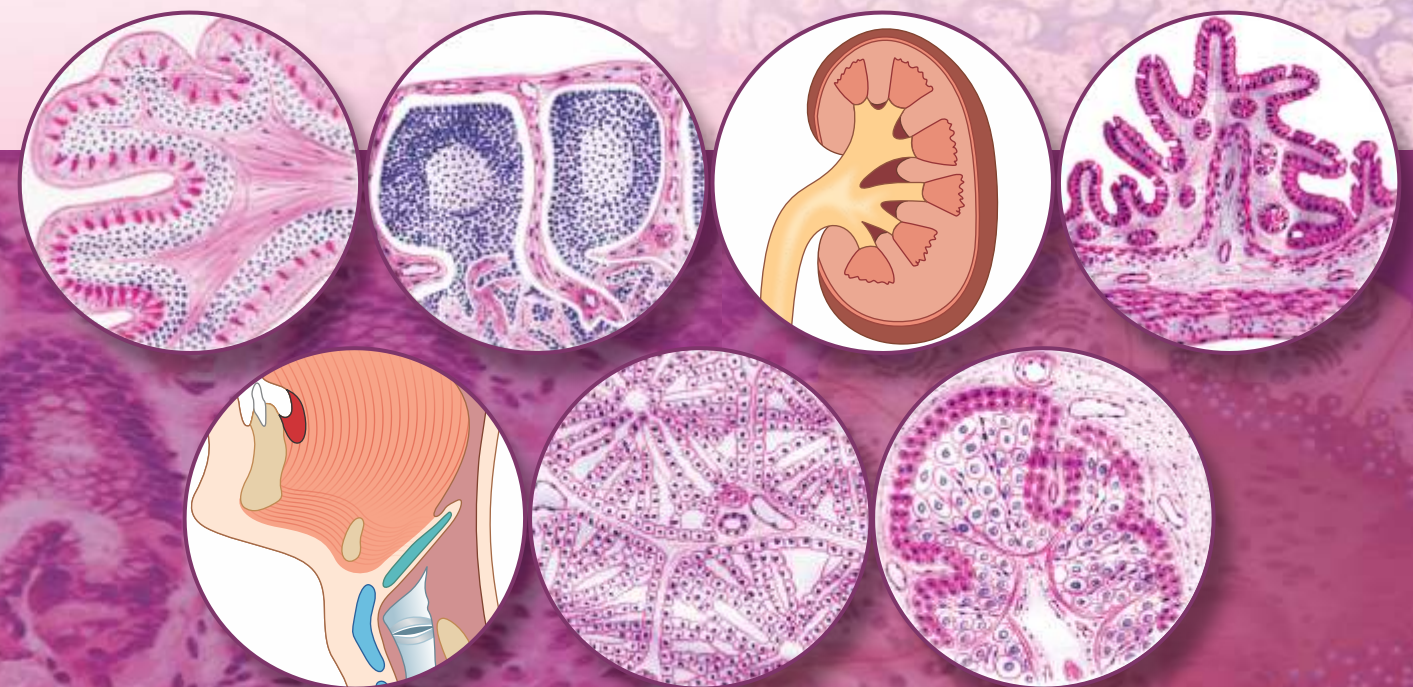
Second Edition

Practical Manual of Histology

Second Edition

Practical Manual of Histology

As per the latest CBME Guidelines | Competency Based Undergraduate Curriculum for the Indian Medical Graduate



Hina Sharma



Dedicated to Education

CBS Publishers & Distributors Pvt Ltd



Practical Manual of Histology

Second Edition

As per CBME Guidelines | Competency Based Undergraduate
Curriculum for the Indian Medical Graduate

Name

Year Roll no.

Name of the College

Teacher's Signature

This is to certify that Mr/Ms _____ 1st year MBBS student of batch _____ has attained the knowledge and skill to identify all types of epithelia under the microscope and describe the various types that correlate to its function.

Signature and seal of the Head
Department of Anatomy

Signature and seal of the Dean

This is to certify that Mr/Ms _____ 1st year MBBS student of batch _____ has attained the knowledge and skill to identify, draw and label a slide of trachea and lung.

Signature and seal of the Head
Department of Anatomy

Signature and seal of the Dean



Practical Manual of **Histology**

Second Edition

As per CBME Guidelines | Competency Based Undergraduate
Curriculum for the Indian Medical Graduate

Hina Sharma MBBS, MD (Anatomy)

Associate Professor
Department of Anatomy
Geetanjali Medical College and Hospital
Udaipur, Rajasthan, India




CBS Publishers & Distributors Pvt Ltd

New Delhi • Bengaluru • Chennai • Kochi • Kolkata • Lucknow • Mumbai
Hyderabad • Jharkhand • Nagpur • Patna • Pune • Uttarakhand

Disclaimer

Science and technology are constantly changing fields. New research and experience broaden the scope of information and knowledge. The author has tried her best in giving information available to her while preparing the material for this edition of the book. Although, all efforts have been made to ensure optimum accuracy of the material, yet it is quite possible some errors might have been left uncorrected. The publisher, printer and the author will not be held responsible for any inadvertent errors or inaccuracies.



ISBN: 978-93-5466-374-1

Copyright © Author and Publisher

Second Edition: 2022

First Edition: 2020

Reprint 2021

All rights reserved. No part of this book may be reproduced or transmitted in any form or by any means, electronic or mechanical, including photocopying, recording, or any information storage and retrieval system without permission, in writing, from the author and publisher.

Published by Satish Kumar Jain and produced by Varun Jain for

CBS Publishers & Distributors Pvt Ltd

4819/XI Prahlad Street, 24 Ansari Road, Daryaganj, New Delhi 110 002, India.

Ph: 011-23289259, 23266861, 23266867

Fax: 011-23243014

Website: www.cbspd.com

e-mail: delhi@cbspd.com; cbspubs@airtelmail.in

Corporate Office: 204 FIE, Industrial Area, Patparganj, Delhi 110 092

Ph: 011-4934 4934 Fax: 011-4934 4935 e-mail: publishing@cbspd.com; publicity@cbspd.com

Branches

- **Bengaluru:** Seema House 2975, 17th Cross, KR Road, Banasankari 2nd Stage, Bengaluru 560 070, Karnataka, India.
Ph: +91-80-26771678/79 Fax: +91-80-26771680 e-mail: bangalore@cbspd.com
- **Chennai:** 7, Subbaraya Street, Shenoy Nagar, Chennai 600 030, Tamil Nadu, India.
Ph: +91-44-26680620/26681266 Fax: +91-44-42032115 e-mail: chennai@cbspd.com
- **Kochi:** 42/1325, 26, Power House Road, Opp KSEB, Ernakulam 682 018, Kochi, Kerala, India.
Ph: +91-484-4059061-65 Fax: +91-484-4059065 e-mail: kochi@cbspd.com
- **Kolkata:** 147, Hind Ceramics Compound, 1st Floor, Nilgunj road, Belghoria, Kolkata 700 056, West Bengal, India.
Ph: +91-33-25633055/56 e-mail: kolkata@cbspd.com
- **Lucknow:** Basement, Khushnuma Complex, 7-Meerabai Marg (behind Jawahar Bhawan), Lucknow 226 001, Uttar Pradesh, India.
Ph: +91-552-4000032 e-mail: tiwari.lucknowi@cbspd.com
- **Mumbai:** PWD shed, Gala No. 25/26, Ramchandra Bhatt Marg, Next to JJ Hospital Gate No. 2, Opp. Union Bank of India, Noorbaug, Mumbai 400 009, Maharashtra, India.
Ph: +91-22-66661880/89 e-mail: mumbai@cbspd.com

Representatives

- | | | | | | |
|--------------------|--------------|--------------------|--------------|----------------------|--------------|
| • Hyderabad | 0-9885175004 | • Jharkhand | 0-9811541605 | • Nagpur | 0-9421945513 |
| • Patna | 0-9334159340 | • Pune | 0-9623451994 | • Uttarakhand | 0-9716462459 |

Printed at: Sanjay Printers and Publishers (P) Ltd. Patparganj, Delhi, India

Foreword

It gives me immense pleasure to introduce the *Practical Manual of Histology* as per the latest MCI syllabus. The author of this workbook has written it with the purpose of dealing with the practical aspects of identifying and describing the normal microanatomy of human tissues.

It has a good consortium of specific learning objectives, think and answer, three points of identification and hand-drawn diagrams. The author has addressed the problems encountered by the learners and penned this workbook in a way which will engender faster understanding of the subject.

I hope the students will take full advantage of the crisp dose of knowledge and diagrams provided in this workbook. At a first glance it looks very promising indeed and I wish the author success in her intent of making teaching and learning of histology a fruitful and rewarding experience.

Prof **FS Mehta** MS (General Surgery)
Dean, Geetanjali Medical College and Hospital
Udaipur, Rajasthan
former Superintendent
Rabindra Nath Tagore Medical College and Hospital
Udaipur, Rajasthan, India

Preface to the Second Edition

I am grateful to the Almighty for giving me the opportunity to present the second edition of *Practical Manual of Histology* as per the new guidelines of competency based undergraduate curriculum for the Indian medical graduate.

I am glad for the immense heartening response from my colleagues, seniors, juniors, students, and my teachers. It has given me the strength to improvise on it and come with the second edition. I hope and look forward to similar and more acceptance from the stakeholders.

The features improvised in the second edition are as follows:

1. The color of the diagrams has been made lighter, as seen in H&E staining.
2. Each diagram has been named.
3. The diagrams which have been revised are:
 - a. Small diagrams of cells, collagen fibres, elastic fibres, serous acini and mucous acini and stratified cuboidal epithelium.
 - b. Hyaline cartilage
 - c. Skeletal muscle
 - d. Thyroid gland
 - e. Urinary bladder
 - f. Fallopian tube
4. The extra blank pages have been removed.
5. SDL (Self-directed Learning) pages have been removed.
6. The text and diagram pages have been rearranged to lie next to each other, so that the learner does not have to turn the page to see the features mentioned in the text.

It is my humble effort to make learning of histology easy for the overburdened medical graduate learners. This manual shall be useful in attempting histology questions in the proposed NEXT exam apart from being a complete book in itself for the 1st year of preclinical subjects.

Hina Sharma

Preface to the First Edition

During the years of teaching histology I have experienced the difficulties encountered by the learners. There is a vast choice of literature for the students to pick from. The normal tendency to pick the easiest available means leads to notes borrowed from seniors. It leads to the problem seen in the whispering game—the end product is far from correct.

Another practical problem encountered is that the various textbooks offer various stains, whereas the stain usually used and taught is haematoxylin and eosin (H&E). As such the learner is faced with the dilemma of which diagram to draw.

To address these issues the idea of promoting easy learning by providing hand-drawn diagrams of tissues stained with H&E stain was conceived. The diagrams are self-explanatory and help the learner identify the given tissue.

The highlight of this workbook is that it addresses all the latest competencies of histology given in the new curriculum.

Each slide has been given specific learning objectives. So at the very outset the learner knows what all he has to specifically look for in the given slide.

There are think and answer questions given at places to encourage the learner to use his/her grey cells because the mind sees what the brain knows. So once the learner begins with thinking he knows what to look for.

There is space provided for writing three points of identification of the slide. These will prove invaluable for last moment revision prior to assessments.

SDL pages have been provided for notes or diagrams. Sufficient space has been given to draw the diagrams with exemplary diagram above on the same page, thus removing the tedious process of turning pages to copy while drawing. If smaller diagram is to be drawn, then a smaller circle may be drawn within the larger one.

This workbook is ideal for learning histology in various streams related to health education and is sufficient for preparation of viva voce.

Hina Sharma

Acknowledgements

Writing a book is by far harder than I first thought. Nonetheless it is very rewarding. I thank the Almighty for giving me the opportunity to write this book.

I am eternally grateful to the management of Geetanjali Medical College for encouraging academic excellence and supporting in adopting newer methods of teaching. I am specially grateful to the Dean, Prof FS Mehta, for initiating the idea of writing a workbook, without which I would probably have not even thought of it. He has been very supportive and inspired me to start this work.

Very special thanks to Prof Manjinder Kaur, Head, Department of Physiology, Geetanjali Medical College, for giving me the much required momentum to start writing this workbook. Being the academic officer, she has always been a source of stimulation for academic perfection.

I cannot thank my family, husband Dr DK Sharma, daughter Dr Ila Sharma and son Dr Kartikeya, enough for bearing with me and not being impatient when I could not do some of the chores due to preoccupation. Their constant support was the only reason that this workbook could be completed on time.

My teacher and guide Prof LK Jain has always been a source of inspiration. The knowledge imparted by him is sound, complete and dependable. I thank him for his blessings.

I am grateful to Prof Nikha Bharadwaj for her invaluable support and suggestions.

My colleagues Dr Brijesh, Dr Charu, Dr Meghna and Dr Pritesh have provided an amicable environment and encouraged and appreciated my work. I am very grateful for their reinforcement.

My initial teaching years were very enriching and I thank my then colleagues Prof Ghanshyam Gupta, Prof Seema Prakash, Dr Parveen Ojha and Dr Pooja Dhabai for providing an academically inspiring environment.

I thank Prof GC Agarwal for helping me enhance my knowledge of histology during initial teaching years. He encouraged me to avoid taking a casual approach towards teaching histology.

I wholeheartedly thank Mrs Jyotsana, Mr Biju, Mr Bhagwati, Mr Vinod and Mr Jagdish for their support.

The students have always been a source of inspiration. I thank them for putting their faith in me and giving me the much required compliments.

I am grateful to all my friends for encouraging me to complete this workbook.

I thank the publisher, and the others involved for printing this workbook in such a short notice.

Hina Sharma

Contents

<i>Foreword by Prof FS Mehta</i>	<i>v</i>
<i>Preface to the Second Edition</i>	<i>vii</i>
<i>Preface to the First Edition</i>	<i>ix</i>
<i>Index of Competencies for Histology</i>	<i>xix</i>
<i>Abbreviations</i>	<i>xx</i>

No.	Practical	Page no.	Teacher's signature	Remarks
1	Light Microscope	1		
2	Epithelium Histology	4		
3	Classification of Epithelium	4		
4	Simple Squamous Epithelium	8		
5	Simple Cuboidal Epithelium	10		
6	Simple Columnar Epithelium	12		
7	Simple Ciliated Columnar Epithelium	14		
8	Simple Columnar Epithelium with Brush/Striated Border	16		
9	Stratified Squamous Epithelium (Non-keratinized)	18		
10	Stratified Squamous Epithelium (Keratinized)	20		
11	Stratified Cuboidal Epithelium	22		
12	Stratified Columnar Epithelium	24		
13	Transitional Epithelium (Unstretched Urinary Bladder)	26		
14	Transitional Epithelium (Stretched Urinary Bladder)	28		
15	Pseudostratified Ciliated Columnar Epithelium (Trachea)	30		
16	Olfactory Epithelium	33		
17	Ultrastructure of Epithelium	36		
18	Connective Tissue Histology	40		
19	Loose Areolar Tissue	42		
20	Dense Regular Connective Tissue (Tendon LS)	44		
21	Dense Regular Connective Tissue (Tendon TS)	46		
22	Ultrastructure of Connective Tissue	48		
23	Cartilage	50		

No.	Practical	Page no.	Teacher's signature	Remarks
24	Hyaline Cartilage	52		
25	Elastic Cartilage	54		
26	Fibrocartilage	56		
27	Bone	59		
28	Compact Bone (TS)	60		
29	Compact Bone (LS)	62		
30	Cancellous Bone (Spongy Bone) TS	64		
31	Muscular Tissue	67		
32	Skeletal Muscle (LS)	68		
33	Skeletal Muscle (TS)	70		
34	Cardiac Muscle (LS)	72		
35	Smooth Muscle (LS)	74		
36	Smooth Muscle (TS)	76		
37	Muscle (Ultrastructure)	78		
38	Nervous Tissue	80		
39	Peripheral Nerve (TS)	82		
40	Sensory/Spinal/Dorsal Root Ganglion	84		
41	Autonomic/Sympathetic/Parasympathetic Ganglion	86		
42	Exocrine (Salivary) Glands Histology	88		
43	Sublingual Salivary Gland (Mucous Gland)	90		
44	Parotid Salivary Gland (Serous Gland)	92		
45	Submandibular Salivary Gland (Mixed Gland)	94		
46	Blood Vessels Histology	96		
47	Elastic Artery/Large Artery	98		
48	Muscular Artery/Medium-sized Artery	100		
49	Lymphoid Tissue	102		
50	Lymph Node	103		
51	Spleen	107		
52	Thymus	111		

No.	Practical	Page no.	Teacher's signature	Remarks
53	Palatine Tonsil	115		
54	Integumentary System	119		
55	Thin Skin	120		
56	Thick Skin	122		
57	Respiratory System	125		
58	Trachea	126		
59	Lung	129		
60	Interalveolar Septum	133		
61	Epiglottis	135		
62	Gastrointestinal System	138		
63	Tongue	139		
64	Oesophagus	143		
65	TS through Lower One-third of Oesophagus	144		
66	TS through Upper One-third of Oesophagus	146		
67	TS through Middle One-third of Oesophagus	148		
68	Cardioesophageal Junction	151		
69	Stomach	155		
70	Fundus/Body of Stomach (TS)	156		
71	TS through Pylorus of Stomach	159		
72	Intestines	163		
73	Duodenum	164		
74	Jejunum	166		
75	Ileum	168		
76	Large Intestine	170		
77	Vermiform Appendix	171		
78	TS through Vermiform Appendix	172		
79	Colon	174		
80	Hepatobiliary System	177		
81	Liver	178		

No.	Practical	Page no.	Teacher's signature	Remarks
82	Pancreas	181		
83	Gall Bladder	185		
84	Urinary System	188		
85	Kidney	190		
86	Ureter	193		
87	Urinary Bladder	197		
88	Reproductive System	201		
89	Male Reproductive System	201		
90	Testis	202		
91	Epididymis	205		
92	Vas Deferens/Ductus Deferens	209		
93	Vas Deferens	210		
94	Prostate	213		
95	Penis	217		
96	Female Reproductive System	221		
97	Ovary	222		
98	Uterus	225		
99	Uterus (Proliferative Phase)	226		
100	Uterus (Secretory Phase)	228		
101	Cervix	231		
102	Fallopian Tube/Uterine Tube	235		
103	Placenta	239		
104	Umbilical Cord	242		
105	Corpus Luteum	245		
106	Breast	249		
107	Mammary Gland (Resting)	250		
108	Mammary Gland of Pregnancy	252		
109	Mammary Gland of Lactation	254		

No.	Practical	Page no.	Teacher's signature	Remarks
110	Endocrine Glands	257		
111	Pituitary Gland	257		
112	Thyroid Gland	260		
113	Parathyroid Gland	262		
114	Pineal Gland	264		
115	Suprarenal Gland	267		
116	Central Nervous System	270		
117	Spinal Cord	270		
118	Cerebrum	272		
119	Cerebellum	274		
120	Special Senses	277		
121	Cornea	277		
122	Sclero-corneal Junction	281		
123	Retina	285		
124	Optic Nerve	288		
125	Eyelid	291		
126	Lip	294		
127	Cochlea and Organ of Corti	297		

Guide to Students for Staining Characteristics of Histology Tissues

300

Feedback form

301

SUGGESTED ASSESSMENT CRITERIA

- Complete file with good and accurate diagrams 5 marks
- Complete file but a few (less than 10%) incorrect diagrams 4 marks
- Complete file but mostly (more than 50%) incorrect diagrams 3 marks
- Incomplete file (more than 75% complete) 2 marks
- Incomplete file (less than 75% complete) 1 mark
- No diagrams drawn (less than 25% diagrams drawn) Zero

INDEX OF COMPETENCIES FOR HISTOLOGY

Number	Competencies addressed	Page nos
AN9.2	Breast: Describe the location, extent, deep relations, structure, age changes, blood supply, lymphatic drainage, microanatomy and applied anatomy of breast	249–255
AN25.1	Identify, draw and label a slide of trachea and lung	125–131
AN43.2	Identify, describe and draw the microanatomy of pituitary gland, thyroid, parathyroid gland, tongue, salivary glands, tonsil, epiglottis, cornea, retina	257–263, 139–142, 88–95, 115–117, 136–137, 178–187
AN43.3	Identify, describe and draw microanatomy of olfactory epithelium, eyelid, lip, sclera-corneal junction, optic nerve, cochlea-organ of Corti, pineal gland	33–35, 291–295, 288–289, 297–299, 264–265
AN52.1	Describe and identify the microanatomical features of gastro-intestinal system: Oesophagus, fundus of stomach, pylorus of stomach, duodenum, jejunum, ileum, large intestine, appendix, liver gall bladder, pancreas and suprarenal gland	143–187, 268–269
AN52.2	Describe and identify the microanatomical features of: Urinary system: Kidney, ureter and urinary bladder Male reproductive system: Testis, epididymis, vas deferens, prostate and penis Female reproductive system: Ovary, uterus, uterine tube, cervix, placenta and umbilical cord	188–248
AN52.3	Describe and identify the microanatomical features of cardioesophageal junction, corpus luteum	151–153, 245–247
AN64.1	Describe and identify the microanatomical features of spinal cord, cerebellum and cerebrum	270–275
AN65.1	Identify epithelium under the microscope and describe the various types that correlate to its function	4–35
AN65.2	Describe the ultrastructure of epithelium	36–39
AN66.1	Describe and identify various types of connective tissue with functional correlation	40–47
AN66.2	Describe the ultrastructure of connective tissue	48–49
AN67.1	Describe and identify various types of muscle under the microscope	67–79
AN67.2	Classify muscle and describe the structure–function correlation of the same	78–79
AN67.3	Describe the ultrastructure of muscular tissue	78–79
AN68.1	Describe and identify multipolar and unipolar neuron, ganglia, peripheral nerve	80–83
AN68.2	Describe the structure–function correlation of neuron	80–81
AN68.3	Describe the ultrastructure of nervous tissue	80–81
AN69.1	Identify elastic and muscular blood vessels, capillaries under the microscope	96–101
AN69.2	Describe the various types and structure–function correlation of blood vessels	96
AN69.3	Describe the ultrastructure of blood vessels	97
AN70.1	Identify exocrine gland under the microscope and distinguish between serous, mucous and mixed acini	88–95
AN70.2	Identify the lymphoid tissue under the microscope and describe microanatomy of lymph node, spleen, thymus, tonsil and correlate the structure with function	102–117
AN71.1	Identify bone under the microscope; classify various types and describe structure–function correlation of the same	59–65
AN71.2	Identify cartilage under the microscope and describe various types and structure–function correlation of the same	50–57
AN72.1	Identify the skin and its appendages under the microscope and correlate the structure with function	119–123

Note: Competency numbers are as provided in the new curriculum.

ABBREVIATIONS

1. SLO: Specific learning objectives
2. H&E: Haematoxylin and eosin
3. LS: Longitudinal section
4. ECM: Extracellular matrix
5. BM: Bone marrow
6. LN: Lymph node
7. WBC: White blood cells
8. RBCs: Red blood cells
9. RER: Rough endoplasmic reticulum
10. SER: Smooth endoplasmic reticulum