

Competency-Based
BD Chaurasia's
Human Anatomy

Regional and Applied | Dissection and Clinical

Ninth
Edition

Volume
2

Volume 1 UPPER LIMB and THORAX
Volume 2 LOWER LIMB, ABDOMEN and PELVIS
Volume 3 HEAD and NECK
Volume 4 BRAIN-NEUROANATOMY

Widely acclaimed as a standard textbook in view of its simple language, comprehensive coverage, lucid presentation and neatly-drawn line diagrams, **BD Chaurasia's Human Anatomy** remains the most preferred textbook in India and abroad. This edition has been thoroughly revised and updated to make it extremely informative and much more student-friendly.

The ninth edition now features diagrams adapted from the first edition, originally prepared by Dr BD Chaurasia, which have been suitably redrawn, modified and colored appropriately. Many text chapters have citations to videos of osteology and soft parts which are accessible through CBSiCentral App. Clinically oriented FAQs and MCQs, and ECE cases have been included to make the volumes absolutely clinical in nature.

Salient features of the four volumes

- Text follows the **CBME Guidelines** and all topics are described as per the **Competency Based Undergraduate Curriculum for the Indian Medical Graduate** prescribed by the National Medical Commission.
- **Colour codes** used consistently in the drawings of various cells, tissues and organs are given at the beginning of each section.
- Impressive **line diagrams**, originally hand-drawn by Dr BD Chaurasia, adapted from the first edition of *BDC Human Anatomy*, have been incorporated in this edition to make drawing of illustrations easier for the students.
- **Videos of osteology and soft parts**, accessible from CBSiCentral App through scratch code, have been numbered and cited in the respective chapters in all the four volumes. The App also includes answers to FAQs.
- **Latest updates** on various topics have been provided from standard international publications.
- **Clinical orientation** has been enthused by structuring many FAQs and MCQs in 'clinical mode'. **Early Clinical Exposure (ECE)** has been provided in the form of signs, symptoms, investigations and treatment of a particular case.
- Important features like **viva voce questions**, **molecular regulation**, **clinicoanatomical problems**, **ossification**, **dissection (steps)** are continued from the previous editions.
- **This volume features**
Tables **52**, Flowcharts **4**, Illustrations **653**, Ossification boxes **12**, Dissection boxes **36**, X-rays **5**, Clinical Anatomy boxes **101**, Facts to Remember **229**, FAQs **132**, MCQs **232**, Viva Voce questions **508**, Videos **50**, Clinicoanatomical Problems **35**.

Chief Editor

Krishna Garg MBBS, MS, PhD, FIMSA, FIAMS, FAMS, FASI is ex-Professor and Head, Department of Anatomy, Lady Hardinge Medical College (LHMC), New Delhi. She joined LHMC where she completed her MS and PhD and taught anatomy till her retirement. She has received fellowships of the Indian Medical Association, Academy of Medical Specialists, and the International Medical Science Academy. She was elected fellow of the Academy of Medical Sciences (FAMS) in 2005. She was honoured with Excellence Award in Anatomy in 2004 by Delhi Medical Association. She has received Life Time Achievement Award, Fellowship of Anatomical Society of India, and DMA Distinguished Services Award, in 2015. She is visiting faculty of DNB, MDS and a PhD examiner.

She is author of *Manual of Human Anatomy Dissection*, *Companion Pocketbook—BDC Human Anatomy* (Vols 1–3) and *BDC Human Anatomy for Dental Students 3/e*; coauthor of *Textbook of Histology 5/e*, *Textbook of Neuroanatomy 6/e*, *Anatomy and Physiology for Nurses*, *Anatomy and Physiology for Allied Health Sciences*, *Practical Anatomy Workbook*, *Practical Histology Workbook* and *Practical Anatomy Workbook for Dental Students*; and editor of *Human Embryology 2/e*, *Handbook of General Anatomy 6/e* and *BD Chaurasia's Applied Anatomy and Physiology for BSc Nursing Students*.

Editors

PS Mittal MBBS, MS is Professor, Department of Anatomy, Government Institute of Medical Sciences, Greater Noida, UP.

Mrudula Chandrupatla MBBS, MD is Additional Professor and Head, Department of Anatomy, and Associate Dean (Research), All India Institute of Medical Sciences, Bibinagar, Hyderabad, Telangana.



CBS Publishers & Distributors Pvt Ltd

4819/XI, Prahlad Street, 24 Ansari Road, Daryaganj, New Delhi 110 002, India
E-mail: delhi@cbspd.com, customercare@cbspd.com; Website: www.cbspd.com
New Delhi | Bengaluru | Chennai | Kochi | Kolkata | Lucknow | Mumbai
Hyderabad | Jharkhand | Nagpur | Patna | Pune | Uttarakhand



Volume
2

Competency-Based
Chaurasia's
Human Anatomy

Ninth
Edition



Competency-Based
BD Chaurasia's
Human Anatomy

Regional and Applied | Dissection and Clinical

As per the CBME Guidelines | Competency Based Undergraduate Curriculum for the Indian Medical Graduate

Lower Limb
Abdomen and Pelvis


Scratch Code on Inside Front Cover for Accessing CBSiCentral App

Available Free on CBSiCentral App

- Original Images from First Edition of BDC Human Anatomy (Vols 1–3) hand-drawn by Dr BD Chaurasia
- Videos on Osteology and Soft Parts
- Frequently Asked Questions & Answers



Wall Chart on Veins of Human Body

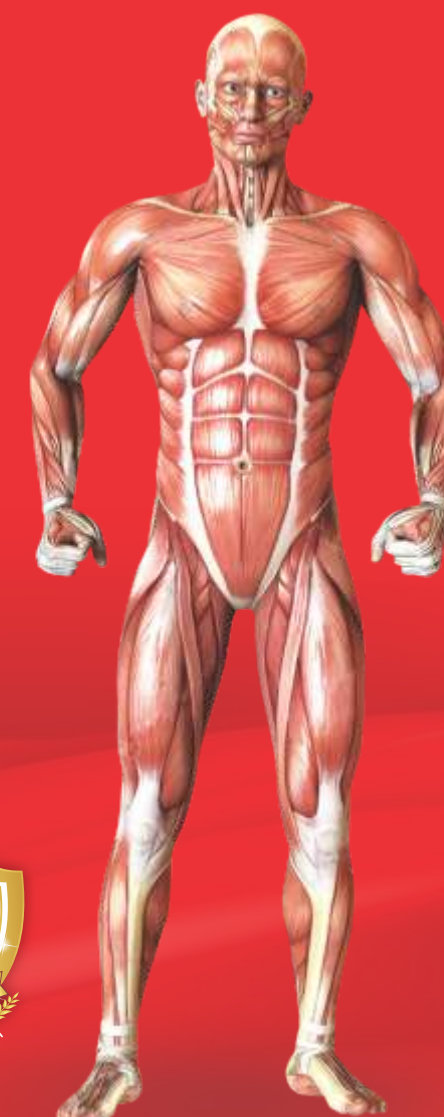

Many easily reproducible diagrams, originally hand-drawn by Dr BD Chaurasia, now modified and coloured suitably, are given at the relevant locations in the text



Dedicated to Education

CBS Publishers & Distributors Pvt Ltd



Ninth Edition

Volume



2

Competency-Based

BD Chaurasia's

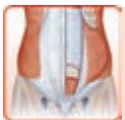Human Anatomy

Regional and Applied **Dissection and Clinical**

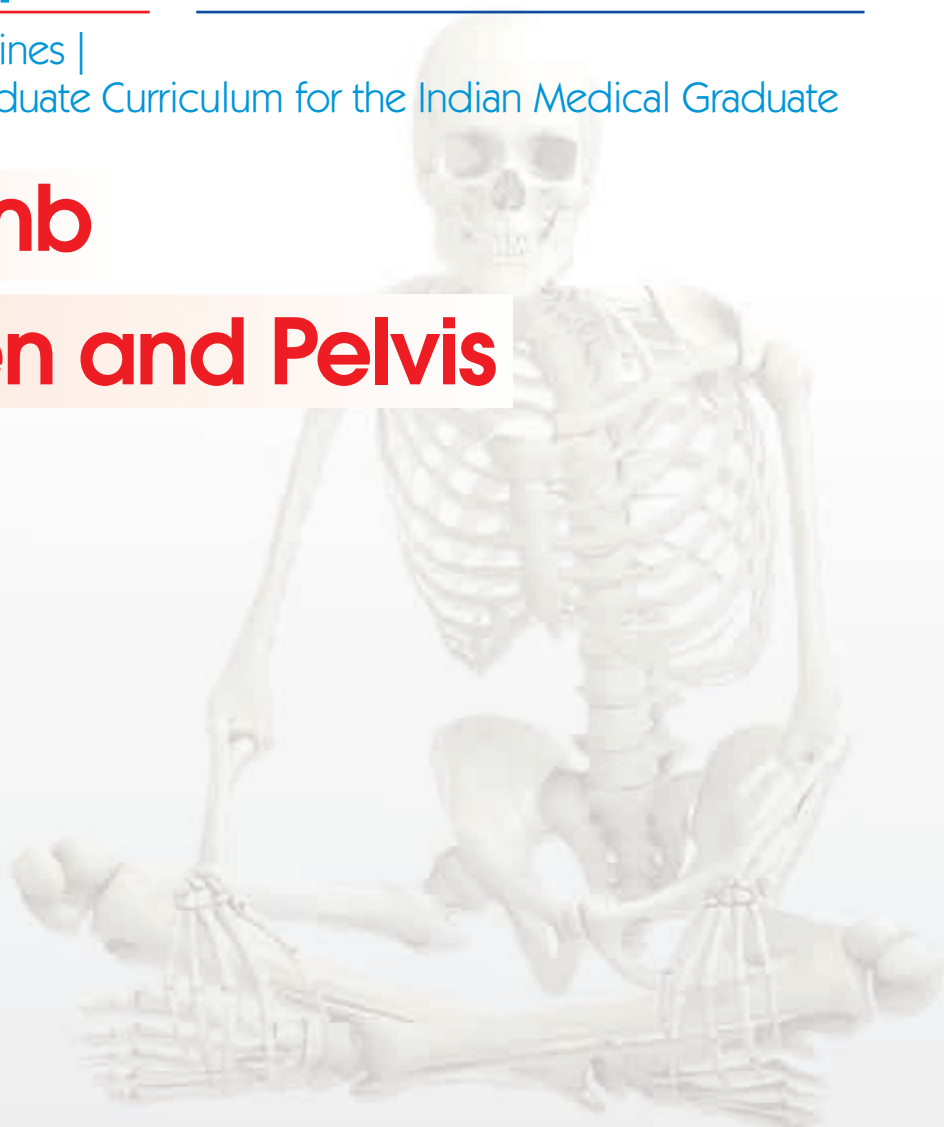
As per the latest CBME Guidelines |
Competency based Undergraduate Curriculum for the Indian Medical Graduate



Lower Limb



Abdomen and Pelvis





Dr BD Chaurasia (1937–1985)

was Reader in Anatomy at GR Medical College, Gwalior.

He received his MBBS in 1960, MS in 1965 and PhD in 1975.

He was elected fellow of National Academy of Medical Sciences (India) in 1982.

He was a member of the Advisory Board of the *Acta Anatomica* since 1981,
member of the editorial board of *Bionature*, and in addition
member of a number of scientific societies.

He had a large number of research papers to his credit.

Ninth Edition

Volume

2

Competency-Based

BD Chaurasia's

Human Anatomy

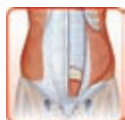Regional and Applied Dissection and Clinical

As per the latest CBME Guidelines |

Competency based Undergraduate Curriculum for the Indian Medical Graduate



Lower Limb



Abdomen and Pelvis

Chief Editor

Krishna Garg

MBBS MS PhD FIMSA FIAMS FAMS FASI

Legend of Anatomy; Nation's Who's Who

Fellow, Anatomical Society of India

Lifetime Achievement Awardee

DMA Distinguished Service Awardee

Ex-Professor and Head, Department of Anatomy

Lady Hardinge Medical College, New Delhi

Editors

Mrudula Chandrupatla MBBS MD

Additional Professor and Head, Department of Anatomy

All India Institute of Medical Sciences

Bibinagar, Hyderabad, Telangana

Pragati Sheel Mittal MBBS MS

Associate Professor, Department of Anatomy


Government Institute of Medical Sciences

Greater Noida, UP



CBS Publishers & Distributors Pvt Ltd

New Delhi • Bengaluru • Chennai • Kochi • Kolkata • Lucknow • Mumbai
Hyderabad • Jharkhand • Nagpur • Patna • Pune • Uttarakhand



Disclaimer

Science and technology are constantly changing fields. New research and experience broaden the scope of information and knowledge. The editors have tried their best in giving information available to them while preparing the material for this book. Although, all efforts have been made to ensure optimum accuracy of the material, yet it is quite possible some errors might have been left uncorrected. The publisher, the printer and the editors will not be held responsible for any inadvertent errors, omissions or inaccuracies.

ISBN: 978-93-5466-476-2

Copyright © Publisher and author

Ninth Edition: 2023

First Edition: 1979

Reprint: 1980, 1981, 1982, 1983, 1984, 1985, 1986, 1987, 1988

Second Edition: 1989

Reprint: 1990, 1991, 1992, 1993, 1994

Third Edition: 1995

Reprint: 1996, 1997, 1998, 1999, 2000, 2001, 2002, 2003, 2004

Fourth Edition: 2004

Reprint: 2005, 2006, 2007, 2008, 2009

Fifth Edition: 2010

Reprint: 2011, 2012

Sixth Edition: 2013

Reprint: 2014, 2015

Seventh Edition: 2016

Reprint: 2017, 2018, 2019

Eighth Edition: 2020

Reprint: 2021, 2022

All rights reserved. No part of this book may be reproduced or transmitted in any form or by any means, electronic or mechanical, including photocopying, recording, or any information storage and retrieval system without permission, in writing, from the author, editors and the publisher.

Published by Satish Kumar Jain and produced by Varun Jain for

CBS Publishers & Distributors Pvt Ltd

4819/XI Prahlad Street, 24 Ansari Road, Daryaganj, New Delhi 110 002, India

Ph: 011-23289259, 23266861, 23266867 Fax: 011-23243014

Website: www.cbspd.com

e-mail: delhi@cbspd.com; cbspdubs@airtelmail.in

Corporate Office: 204 FIE, Industrial Area, Patparganj, Delhi 110 092, India

Ph: 011-4934 4934

Fax: 011-4934 4935

e-mail: publishing@cbspd.com; publicity@cbspd.com

Branches

- **Bengaluru:** Seema House 2975, 17th Cross, KR Road, Banasankari 2nd Stage, Bengaluru 560 070, Karnataka, India
Ph: +91-80-26771678/79 Fax: +91-80-26771680 e-mail: bangalore@cbspd.com
- **Chennai:** 7, Subbaraya Street, Shenoy Nagar, Chennai 600 030, Tamil Nadu, India
Ph: +91-44-26680620, 26681266 Fax: +91-44-42032115 e-mail: chennai@cbspd.com
- **Kochi:** 42/1325, 1326, Power House Road, Opp KSEB, Power House, Ernakulum Kochi 682 018, Kerala, India
Ph: +91-484-4059061-65,67 Fax: +91-484-4059065 e-mail: kochi@cbspd.com
- **Kolkata:** 147, Hind Ceramics Compound, 1st Floor, Nilgunj Road, Belghoria, Kolkata-700056, West Bengal, India
Ph: +033-256330055/56 e-mail: kolkata@cbspd.com
- **Lucknow:** Basement, Khushnuma Complex, 7 Meerabai Marg (Behind Jawahar Bhawan), Lucknow-226001, UP, India
Ph: +0522-4000032 e-mail: tiwari.lucknow@cbspd.com
- **Mumbai:** PWD Shed, Gala no 25/26, Ramchandra Bhatt Marg, Next to JJ Hospital Gate no. 2, Opp. Union Bank of India, Noorbaug, Mumbai-400009, Maharashtra, India
Ph: 022-66661880/89 e-mail: mumbai@cbspd.com

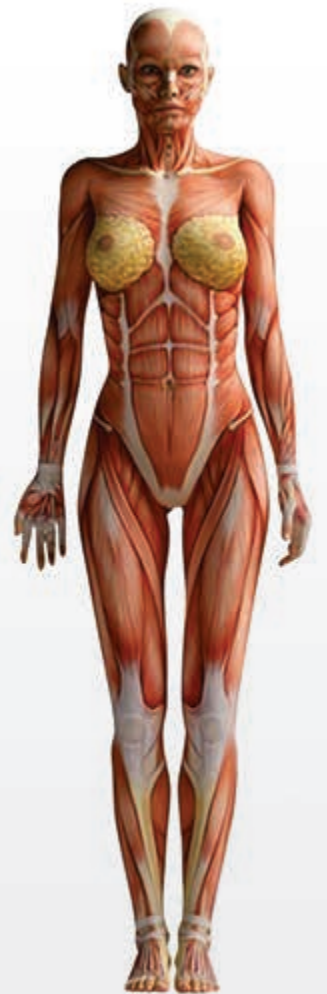Representatives

- | | | |
|--------------------------|--------------------------|----------------------------|
| • Hyderabad 0-9885175004 | • Jharkhand 0-9811541605 | • Nagpur 0-9421945513 |
| • Patna 0-9334159340 | • Pune 0-9623451994 | • Uttarakhand 0-9716462459 |

Printed at Thomson Press (India) Ltd., Delhi, India

to

my teacher
Shri Uma Shankar Nagayach
— BD Chaurasia



Volume

1

UPPER LIMB and THORAX

Volume

2

LOWER LIMB, ABDOMEN and PELVIS

Volume

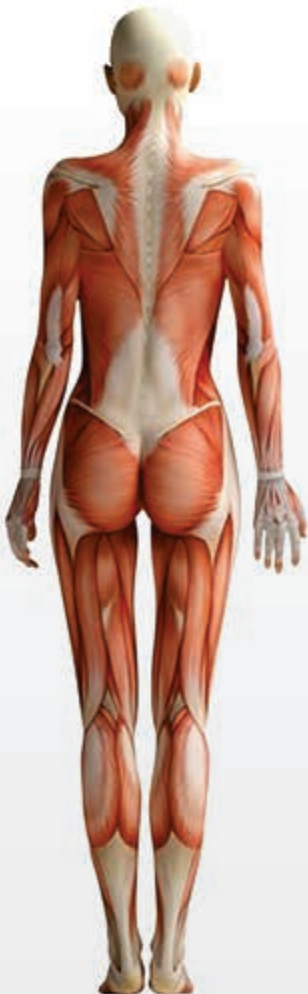3

HEAD and NECK

Volume

4

BRAIN-NEUROANATOMY



*This human anatomy is not systemic but regional
Oh yes, it is theoretical as well as practical
Besides the gross features, it is chiefly clinical
Clinical too is very much diagrammatical.*

*Lots of tables for the muscles are provided
Even methods for testing are incorporated
Improved colour illustrations are added
So that right half of brain gets stimulated*

*Tables for muscles acting on joints are given
Tables for branches of nerves and arteries are given
Hope these volumes turn highly useful
Editors' hardwork under Almighty's guidance prove fruitful*

Preface to the Ninth Edition



This edition features a number of significant modifications which we have made in the light of the wide-ranging suggestions that we received in the recent months from students, teachers and also the well-wishers of this epic textbook. As the information explodes and knowledge multiplies, appropriate improvements, additions and changes are also required to be made in the contemporary literature. Latest research information sourced from the standard international publications has been selectively incorporated in these volumes.

Numerous unique line diagrams, originally hand-drawn by late Dr BD Chaurasia and used in the first edition of the book, after thoughtful moderation, have now been incorporated in the ninth edition. Our criteria for the selection and manipulation of these drawings were clearly based on the simplicity and lucidity of the anatomic description. These simply structured illustrations can be easily reproduced by the students in multitudes of tests and examinations, including university examinations.

Diagrams form the foundation of anatomy: The drawings create imprints on the brain. Figures, artwork and the dissection are recorded in the right half of the cerebrum while the text is learnt by using left half of cerebrum. Thus, learning by drawing diagrams and steps of dissection help in using both the halves of cerebrum, which is an ideal condition. This textbook lays stress on understanding anatomic structures and details through clear, neat and crisp diagrams.

Earlier, videos of the dissection of all regions had been given free access to the readers on [CBSiCentral App](#). These videos are now uploaded on the App after reorganization of the sequences, numeration and providing appropriate citations in the text. Readers can register on the App and access the enumerated videos through the scratch code given on the inside front cover of each volume. These videos adequately compensate the scarcity of the cadavers in medical institutions for conducting dissection.

The videos of the dissection give three-dimensional image descriptions of tissues and organs which get effectively registered in brain for a longer time.

Processes and steps of dissection given in blue boxes with dissection photographs have been retained as many students and teachers appreciate the same. However, no addition in dissection photographs has been made as a separate CBSPD publication *Manual of Human Anatomy Dissection* (ISBN: 978-93-89688-00-9) with numerous dissection photographs is available to the readers who aspire to learn and enjoy the dissection in a meticulous manner.

We have incorporated all the competencies prescribed by National Medical Commission under the [Competency Based Curriculum for the Indian Medical Graduate](#) for spirited implementation of [Competency Based Medical Education Guidelines](#).

Since National Medical Commission has laid stress on teaching and learning clinical aspects from the very beginning of the MBBS study period, the questions asked are mostly clinical. [Clinical aspects](#) have been explicitly given in the text such that the students are able to learn, recapitulate and answer the clinically-oriented questions in their examinations.

As NMC curriculum also lays emphasis on [Early Clinical Exposure](#), crisply written and well-presented [ECE Cases](#) have been given at the end of every section, which make the book clinical-savvy. These case studies will help the budding doctors in imbibing the salient clinical features, getting appropriate investigations done, and treating the patients satisfactorily once they are in clinical practice.

All the illustrations in the four volumes of this book have been prepared on a common colour scheme applicable to cells, tissues and organs. Colour codes employed in the preparation of the human anatomy illustrations are given in the beginning of each section. This characteristic feature will help the students in identifying the anatomic components clearly and draw appropriately coloured diagram in a schematic manner.

Extensive research by numerous scientists has decoded the molecular control of development of organ tissues of the body. Basics of this molecular control are given briefly in these volumes.

We have continued with the practice of giving one separate **wall chart** in each volume for easy comprehension of the topics.

Sincere attempt has been made to present all facets of theory and practical anatomy to make these volumes truly holistic. In addition to the descriptive text, the following rich features lend a high pedestal to the book in the context of the international literature.

	<i>Volume 1</i>	<i>Volume 2</i>	<i>Volume 3</i>	<i>Volume 4</i>	<i>Total</i>
Figures	414	653	462	210	1739
Flowcharts	7	4	12	9	32
Dissection Boxes	37	36	12	5	90
X-rays/MRI and CT Scans	5	5	4	16	30
Ossification Boxes	13	12	14	–	39
Tables	43	52	33	23	151
Clinical Anatomy Boxes	52	101	77	41	271
Mnemonics Boxes	22	15	8	4	49
Facts to Remember	93	229	114	67	503
FAQs	99	132	104	52	387
MCQs	149	232	135	72	588
Viva Voce Questions	259	508	227	125	1119
Clinicoanatomical Problems	19	35	20	14	88
Videos	47	50	32	9	138

Chief Editor

Krishna Garg

email: dr.krishnagarg@gmail.com

Editors

Pragati Sheel Mittal
Mrudula Chandrupatla

Preface to the First Edition (excerpts)

The necessity of having a simple, systematized and complete book on anatomy has long been felt. The urgency for such a book has become all the more acute due to the shorter time now available for teaching anatomy, and also to the falling standards of English language in the majority of our students in India. The national symposium on 'Anatomy in Medical Education' held at Delhi in 1978 was a call to change the existing system of teaching the unnecessary minute details to the undergraduate students.

This attempt has been made with an object to meet the requirements of a common medical student. The text has been arranged in small classified parts to make it easier for the students to remember and recall it at will. It is adequately illustrated with simple line diagrams which can be reproduced without any difficulty, and which also help in understanding and memorizing the anatomical facts that appear to defy memory of a common student. The monotony of describing the individual muscles separately, one after the other, has been minimised by writing them out in tabular form, which makes the subject interesting for a lasting memory. The relevant radiological and surface anatomy have been treated in separate chapters. A sincere attempt has been made to deal, wherever required, the clinical applications of the subject. The entire approach is such as to attract and inspire the students for a deeper dive in the subject of anatomy.

The book has been intentionally split in three parts for convenience of handling. This also makes a provision for those who cannot afford to have the whole book at a time.

It is quite possible that there are errors of omission and commission in this mostly single-handed attempt. I would be grateful to the readers for their suggestions to improve the book from all angles.

I am very grateful to my teachers and the authors of numerous publications, whose knowledge has been freely utilised in the preparation of this book. I am equally grateful to my professor and colleagues for their encouragement and valuable help. My special thanks are due to my students who made me feel their difficulties, which was a great incentive for writing this book. I have derived maximum inspiration from Prof. Inderbir Singh (Rohtak), and learned the decency of work from Shri SC Gupta (Jiwaji University, Gwalior).

I am deeply indebted to Shri KM Singhal (National Book House, Gwalior) and Mr SK Jain (CBS Publishers & Distributors, Delhi), who have taken unusual pains to get the book printed in its present form. For giving it the desired get-up, Mr VK Jain and Raj Kamal Electric Press are gratefully acknowledged. The cover page was designed by Mr Vasant Paranjpe, the artist and photographer of our college; my sincere thanks are due to him. I acknowledge with affection the domestic assistance of Munne Miyan and the untiring company of my Rani, particularly during the odd hours of this work.

BD Chaurasia



Acknowledgements

The editors are thankful to Dr SN Kazi (Pune) for providing maximum updates from Gray's Anatomy, 42nd Edition.

Dr Vikas Verma (Lucknow) revised the chapters on Joints and Nerves of Limbs and gave very useful inputs. Dr Tripta Bhagat (Ghaziabad) edited clinical anatomy portions of the volumes.

We have the blessings and good wishes of Prof NA Faruqi (Aligarh); Dr DC Naik (Rewa); Dr SD Joshi and Dr SS Joshi (Indore); Dr (Brig) Rakesh Gupta (Greater Noida); Dr DR Singh (Lucknow); Dr M Kaul; Dr C Anand and Dr I Bahl (Delhi); Dr Mohsin Azmi (Kanpur); Dr Medha Joshi (Ghaziabad); Dr Surbhi Gupta (Delhi); and Dr Nitin Nagarkar (Raipur).

We are thankful to Dr Surjit Ghatak (Jodhpur); Dr Vinay Sharma (Muzzafarnagar); Dr Deepu Singh Kataria and Dr Anup Singh Gurjar (Pali); Dr Jagmohan Sharma; Dr Deepak Sharma; Dr Rajesh Arora and Dr Pooja Garg (Jaipur); Dr Sumit Gupta (Kota); Dr Gopal Sharma and Dr Manoj Sharma (Jhalawar); Dr Rekha Parashar (Chittorgarh); Dr Santosh Kumar (Dholpur); Dr BK Aghera (Sirohi); Dr Isha Srivastav; Dr Aprajita Raizada; Dr Sajjan Skaria; Dr Anjali Jain and Dr Kalpana Sharma (Udaipur); for giving feedback for various sections of the volumes.

We are grateful to Dr Hitant Vohra and Dr Anu Sharma (Ludhiana); Dr Anupma Mahajan (Amritsar); Dr Vanita Gupta (Jammu), for editing chapters to enhance the value of the volumes.

We are grateful to Dr Ravikant (Amritsar); Dr Sangeeta and Dr Nusrat Jabeen (Jammu); Dr Kalyan Singh and Dr Rajan Singla (Patiala); Dr Anjali Jain and Dr Aprajita Sikka (Ludhiana); Dr Bashir (Srinagar); Dr Seema and Dr Ritu (Rajouri); Dr Mubeen (Kathua); Dr RK Srivastava (Kanpur); Dr Punita Manik (Lucknow); Dr Binod Kumar; Dr Sunita Nayak and Dr Shambhu Prasad (Patna); Dr AK Dubey (Ranchi); Dr Satyam Khare; Dr Shilpi Jain and Dr Alok Tripathi (Meerut), for promoting the volumes.

We have been getting constant encouragement and support from Dr Ranjana Verma, Dr Muthukrishnan P, Dr Yogesh Yadav, Dr Pullimi Vineel and Dr Anupma Gupta (Greater Noida); Dr Nisha Kaul (Ghaziabad); Dr Vinay Singhal (Saharanpur); Dr RK Ashoka (Mathura); Dr Vineet Guha (Khandwa); Dr Manisha Sinha (Raipur); Dr Jahan Shirin (Kanpur); Dr Damyanti (Manipur); Dr Daisy Sahni (Chandigarh); and Dr MK Anand (Bhuj).

Our regards and affection to Dr Rewa Choudhry, Dr Shilpa Paul, Dr Smita Kakar, Dr Anita Tuli, Dr Gayatri Rath, Dr Shashi Raheja, Dr Shyama Rajdan, Dr Mangala Kohli, Dr A Sheriff, Dr SB Ray, Dr Vandana Mehta, Dr Sabita Mishra, Dr Renu Chauhan, Dr Jyoti Arora, Dr Sneha Aggarwal and Dr TS Roy (Delhi), for going through the volumes.

We would like to thank Dr Pritha Bhuiyan (Mumbai); Dr Brijendra Singh (Rishikesh); Col. Dr Sushil Kumar (Pune); Dr AK Srivastava (Lucknow); Dr MK Pant (Dehradun); Dr Shakuntala Pai (Manipal); Dr Simmi Mehra (Rajkot); Dr Fatima M De Souza (Goa); Dr Mukesh Mittal (Shivpuri); Dr Priti Sinha (Saharanpur); Dr Rakesh K Verma (Lucknow); Dr Rashmi Malhotra (Rishikesh); Dr Sandiya Kurup (Kanchery); Dr Simmi Soni (Aziznagar); Dr Sunita Gupta (Ahmedabad) and many-many other teachers all over the globe, for giving us good wishes.

Videos of bones and soft parts of human body, prepared at Kathmandu University School of Medical Sciences, have now been added with the respective chapters and are available at our mobile App [CBSiCentral](#). I (chief editor) am grateful to Dr R Koju, CEO of KUSMS and Dhulikhel Hospital, for his generosity.

The moral support of my (chief editor) family members, Late Dr DP Garg, Dr Suvira Gupta, Dr JP Gupta, Mr Manoj, Ms Rekha, Mr Sanjay, Ms Meenakshi, Dr Manish, Dr Shilpa Garg, Dr Naveen Garg, Dr Manoj, Dr Nalini Shukla, Dr Vikas Verma and Dr Swati Gupta, is appreciated.

The magnanimity shown by Mr SK Jain (Chairman) and Mr Varun Jain (Director), CBS Publishers & Distributors, has been always forthcoming. The unquestionable support of Mr YN Arjuna (Senior Vice President—Publishing, Editorial and Publicity) and his entire team comprising Ms Ritu Chawla (GM—Production), Mr Sanjay Chauhan, Mr Neeraj Prasad and Mr Rohan Prasad (Graphic Artists); Mr Surendra Jha and Mr Prasenjit Paul (Copy Editors); Ms Jyoti Kaur and Mr Tarun Rajput (DTP Operators) has made an excellent contribution to bring out this edition. We are really obliged to them and pray for their prosperity.

Chief Editor

Krishna Garg

email: dr.krishnagarg@gmail.com

Editors

**Pragati Sheel Mittal
Mrudula Chandrupatla**

Thus spoke the cadaver

*Handle me with little love and care
As I had missed it in my life affair
Was too poor for cremation or burial
That is why am lying in dissection hall*

*You dissect me, cut me, section me
But your learning anatomy should be precise
Worry not, you would not be taken to court
As I am happy to be with the bright lot*

*Couldn't dream of a fridge for cold water
Now my body parts are kept in refrigerator
Young students sit around me with friends
A few dissect, rest talk, about food, family and movies
How I enjoy the dissection periods
Don't you? Unless you are interrogated by a teacher*

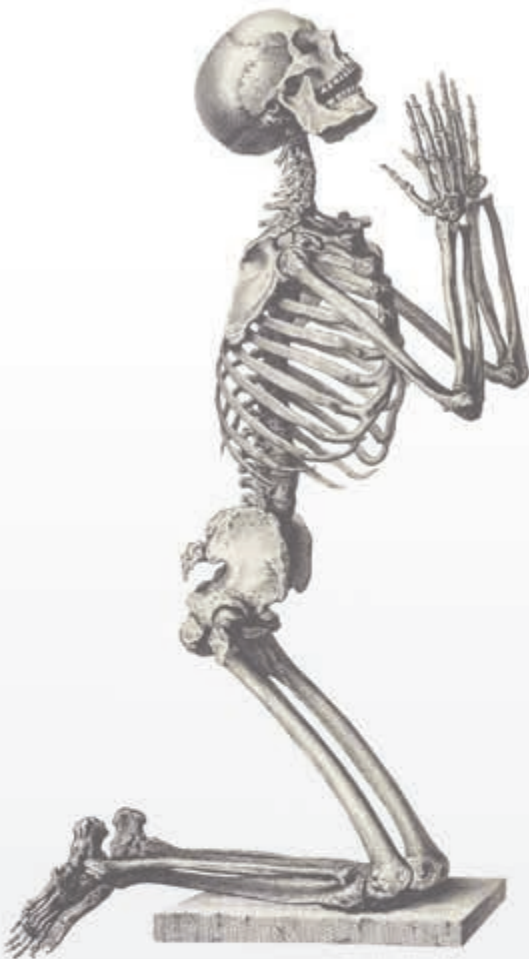*When my parts are buried post-dissection
Bones are taken out for the skeleton
Skeleton is the crown glory of the museum
Now I am being looked up by great enthusiasm*

*If not as skeletons as loose bones
I am in their bags and in their hostel rooms
At times, I am on their beds as well
Oh, what a promotion to heaven from hell*

*I won't leave you, even if you pass anatomy
Would follow you in forensic medicine and pathology
Would be with you even in clinical teaching
Medicine line is one where dead teach the living*

*One humble request I'd make
Be sympathetic to persons with disease
Don't panic, you'll have enough money
And I bet, you'd be singularly happy*

—Krishna Garg



Contents



<i>Preface to the Ninth Edition</i>	vii
<i>Preface to the First Edition (excerpts)</i>	ix
<i>Index of Competencies</i>	xxv

Section 1 LOWER LIMB

1. Introduction 3

Development of Lower Limb	3
Molecular Regulation of Limb Development	4
Parts of the Lower Limb	4
Related Terms	4
Frequently Asked Questions	6
Viva Voce	6

2. Bones 7

Introduction	7
Hip Bone	7
Ilium	7
Pubis	9
Ischium	12
Acetabulum	14
Obturator Foramen	15
Ossification	15
Clinical Anatomy	15
Femur	15
Ossification	21
Clinical Anatomy	21
Patella	23
Ossification	23
Clinical Anatomy	24
Tibia	24
Ossification	28
Clinical Anatomy	29
Fibula	29
Ossification	32
Clinical Anatomy	32
Bones of the Foot	33
Tarsus/Tarsals	33
Talus	33
Ossification	35
Clinical Anatomy	35
Calcaneus or Calcaneum	35
Ossification	37
Clinical Anatomy	37
Navicular Bone	37
Ossification	37
Cuneiform Bones	37
Medial Cuneiform	38
Intermediate Cuneiform	38
Lateral Cuneiform	39
Ossification	39
Cuboid	39
Ossification	40
Metatarsus	40
Ossification	41

Phalanges	41
Ossification	41
Clinical Anatomy	41
Sesamoid Bones	42
Video 2.2.1 Hip Bone	
Video 2.2.2 Femur	
Video 2.2.3 Patella	
Video 2.2.4 Tibia	
Video 2.2.5 Fibula	
Video 2.2.6 Tarsus	
Video 2.2.7 Metatarsals and Phalanges	
Video 2.2.8 Joints of the Foot	
Mnemonics	42
Facts to Remember	42
Clinicoanatomical Problem	42
Further Reading	43
Frequently Asked Questions	43
Multiple Choice Questions	43
Viva Voce	44

3. Front of Thigh 46

Introduction	46
Surface Landmarks	46
Skin and Superficial Fascia	47
Cutaneous Nerves	47
Cutaneous Arteries	48
Great or Long Saphenous Vein	48
Superficial Inguinal Lymph Nodes	49
Subcutaneous Bursae	49
Dissection	50
Clinical Anatomy	50
Deep Fascia	50
Dissection	52
Clinical Anatomy	52
Femoral Triangle	52
Boundaries	52
Contents	53
Femoral Sheath	54
Femoral Canal	55
Clinical Anatomy	55
Femoral Artery	57
Clinical Anatomy	58
Femoral Vein	59
Femoral Nerve	59
Branches and Distribution	59
Clinical Anatomy	60
Muscles of the Front of the Thigh	60
Iliacus and Psoas Major	61
Clinical Anatomy	61

Adductor/Hunter's/Subsartorial Canal 63

Dissection 65

► Video 2.3 Front of Thigh

Facts to Remember 65

Clinicoanatomical Problem 65

Further Reading 65

Frequently Asked Questions 65

Multiple Choice Questions 65

Viva Voce 66

4. Medial Side of Thigh

67

Introduction 67

Adductor Compartment 67

Boundaries 67

Dissection 67

Muscles of Adductor/Medial Compartment of Thigh 68

Relations of Adductor Longus 68

Obturator Nerve 69

Clinical Anatomy 70

Accessory Obturator Nerve 71

Obturator Artery 71

Medial Circumflex Femoral Artery 71

Clinical Anatomy 72

► Video 2.4 Medial Side of Thigh

Facts to Remember 72

Clinicoanatomical Problem 72

Further Reading 72

Frequently Asked Questions 73

Multiple Choice Questions 73

Viva Voce 73

5. Gluteal Region

74

Introduction 74

Surface Landmarks 74

Dissection 75

Superficial and Deep Fascia 75

Superficial Fascia 75

Cutaneous Nerves 75

Cutaneous Vessels and Lymphatics 76

Deep Fascia 76

Muscles of Gluteal Region 76

Structures under Cover of Gluteus Maximus 78

Structures Deep to the Gluteus Medius 80

Structures Deep to the Gluteus Minimus 80

Dissection 80

Clinical Anatomy 80

Sacrospinous and Sacrotuberous Ligaments 82

Nerves of the Gluteal Region 82

Superior Gluteal Nerve 82

Inferior Gluteal Nerve 82

Sciatic Nerve 82

Clinical Anatomy 82

Posterior Cutaneous Nerve of the Thigh 83

Nerve to Quadratus Femoris 83

Pudendal Nerve 83

Nerve to the Obturator Internus 83

Perforating Cutaneous Nerve 83

Arteries of Gluteal Region 84

Superior Gluteal Artery 84

Inferior Gluteal Artery 84

Internal Pudendal Artery 84

Trochanteric Anastomosis 84

Cruciate Anastomosis 84

Structures Passing through the Greater Sciatic

Foramen (Gateway of Gluteal Region) 85

Structures Passing through the Lesser

Sciatic Foramen 85

► Video 2.5 Gluteal Region

Facts to Remember 85

Clinicoanatomical Problem 85

Further Reading 85

Frequently Asked Questions 86

Multiple Choice Questions 86

Viva Voce 86

6. Popliteal Fossa

87

Introduction 87

Surface Landmarks 87

Dissection 87

Location 87

Boundaries 87

Contents 89

Popliteal Artery 89

Clinical Anatomy 90

Popliteal Vein 90

Tibial Nerve in Popliteal Fossa 91

Clinical Anatomy 91

Common Peroneal Nerve 91

Posterior Cutaneous Nerve of Thigh 92

Genicular Branch of Obturator Nerve 92

Popliteal Lymph Nodes 92

Clinical Anatomy 92

Anastomoses Around the Knee Joint 92

► Video 2.6 Popliteal Fossa

Mnemonics 93

Facts to Remember 93

Clinicoanatomical Problem 93

Further Reading 93

Frequently Asked Questions 94

Multiple Choice Questions 94

Viva Voce 94

7. Back of Thigh

95

Introduction 95

Muscles and Nerves 95

Muscles of the Back of Thigh 95

Dissection 95

Clinical Anatomy 95

Sciatic Nerve 99

Clinical Anatomy 100

Arteries of the Back of Thigh 101

Anastomoses on the Back of Thigh 102

► Video 2.7 Back of the Thigh

Facts to Remember 103

Clinicoanatomical Problem 103

Further Reading 103

Frequently Asked Questions 104

Multiple Choice Questions 104

Viva Voce 104

8. Front of Leg with Dorsum of Foot; Lateral and Medial Sides of Leg

105

Introduction 105

Surface Landmarks 105

Superficial Fascia 106

Superficial Veins 106

Cutaneous Nerves 107

Dissection 107
 Clinical Anatomy 107
 Deep Fascia 107
 Superior Extensor Retinaculum 108
 Inferior Extensor Retinaculum 109
 Dissection 109
 Clinical Anatomy 109
 Muscles of Front of Leg 109
 Muscles of Anterior Compartment of the Leg 109
 Anterior Tibial Artery 109
 Deep Peroneal Nerve 113
 Dissection 114
 Clinical Anatomy 115
 Dorsum of Foot 115
 Dorsalis Pedis Artery (Dorsal Artery of the Foot) 115
 Dissection 116
 Clinical Anatomy 116
 Fascia and Muscles of Lateral Side of the Leg 116
 Peroneal Retinacula 116
 Dissection 117
 Clinical Anatomy 117
 Peroneal Muscles 117
 Clinical Anatomy 117
 Superficial Peroneal Nerve 117
 Dissection 118
 Clinical Anatomy 118
 Tendons on Medial Side of the Leg 118
 Dissection 119
 Clinical Anatomy 119
 Video 2.8 Front of Leg
 Mnemonics 119
 Facts to Remember 120
 Clinicoanatomical Problem 120
 Further Reading 120
 Frequently Asked Questions 121
 Multiple Choice Questions 121
 Viva Voce 121

9. Back of Leg

123

Introduction 123
 Superficial Fascia 123
 Small or Short Saphenous Vein 123
 Great or Long Saphenous Vein 123
 Cutaneous Nerves 123
 Dissection 124
 Clinical Anatomy 124
 Deep Fascia 124
 Boundaries and Subdivisions 124
 Flexor Retinaculum 125
 Dissection 125
 Clinical Anatomy 126
 Muscles 126
 Superficial Muscles 126
 Deep Muscles 128
 Dissection 129
 Clinical Anatomy 129
 Posterior Tibial Artery 130
 Peroneal Artery 131
 Tibial Nerve 131
 Clinical Anatomy 132
 Video 2.9 Back of Leg
 Mnemonics 133
 Facts to Remember 133
 Clinicoanatomical Problem 133
 Further Reading 133

Frequently Asked Questions 134
 Multiple Choice Questions 134
 Viva Voce 134

10. Sole of Foot

135

Introduction 135
 Skin 135
 Dissection 136
 Fasciae 136
 Superficial Fascia 136
 Dissection 136
 Deep Fascia 136
 Plantar Aponeurosis 136
 Deep Transverse Metatarsal Ligaments 137
 Fibrous Flexor Sheaths 137
 Clinical Anatomy 137
 Muscles of Sole 137
 Muscles and Tendons of the First and Second Layers 137
 Dissection 138
 Muscles and Tendons of Third and Fourth Layers 139
 Dissection 139
 Plantar Vessels and Nerves 142
 Medial Plantar Nerve 142
 Lateral Plantar Nerve 144
 Dissection 144
 Clinical Anatomy 144
 Medial Plantar Artery 144
 Lateral Plantar Artery 144
 Plantar Arch 145
 Clinical Anatomy 145
 Video 2.10 Foot/Sole
 Facts to Remember 146
 Clinicoanatomical Problem 146
 Further Reading 146
 Frequently Asked Questions 147
 Multiple Choice Questions 147
 Viva Voce 147

11. Venous and Lymphatic Drainage; Segmental and Sympathetic Innervation; and Comparison of Lower and Upper Limbs

148

Introduction 148
 Venous Drainage 148
 Factors Helping Venous Return 148
 Veins of Lower Limb 148
 Long Saphenous Vein 149
 Small or Short Saphenous Vein 150
 Perforating Veins 150
 Clinical Anatomy 151
 Lymphatic Drainage 152
 Classification 152
 Superficial Inguinal Lymph Nodes 152
 Deep Inguinal Lymph Nodes 153
 Superficial Lymphatics 153
 Deep Lymphatics 153
 Clinical Anatomy 154
 Segmental Innervation 154
 Dermatomes 154
 Myotomes 155
 Clinical Anatomy 155
 Sympathetic Innervation 156
 Comparison of Lower and Upper Limbs 156

Facts to Remember 159
 Clinicoanatomical Problem 159
 Further Reading 159
 Frequently Asked Questions 159
 Multiple Choice Questions 160
 Viva Voce 160

12. Joints of Lower Limb

161

Introduction 161
 Hip Joint 161
 Type 161
 Ligaments 161
 Relations of the Hip Joint 163
 Blood Supply 164
 Nerve Supply 164
 Movements 164
 Dissection 164
 Clinical Anatomy 165
 Knee Joint 166
 Type 166
 Ligaments 166
 Dissection 169
 Synovial Membrane 170
 Bursae around the Knee 170
 Relations of Knee Joint 170
 Blood Supply 171
 Nerve Supply 171
 Dissection 171
 Movements at the Knee Joint 171
 Locking and Unlocking of the Knee Joint 172
 Dissection 172
 Clinical Anatomy 173
 Ankle Joint 174
 Ligaments 174
 Relations of the Ankle Joint 176
 Movements 176
 Blood Supply 177
 Nerve Supply 177
 Dissection 177
 Clinical Anatomy 177
 Tibiofibular Joints 177
 Superior Tibiofibular Joint 177
 Middle Tibiofibular Joint 177
 Inferior Tibiofibular Joint 178
 Dissection 178
 Clinical Anatomy 178
 Joints of the Foot 178
 Subtalar or Talocalcaneal Joint 179
 Movements 179
 Talocalcaneonavicular Joint 179
 Movements 180
 Calcaneocuboid Joint 180
 Transverse Tarsal or Midtarsal Joint 181
 Inversion and Eversion of the Foot 181
 Joints Taking Part 181
 Muscles Producing Movements 181
 Dissection 182
 Smaller Joints of Forefoot 182
 Joint Cavities of Foot 182
 Metatarsophalangeal and Interphalangeal Joints 183
 Dissection 183
 Gait/Walking 183
 Clinical Anatomy 183
 Video 2.12 Joints of Lower Limb
 Facts to Remember 184

Clinicoanatomical Problems 184
 Further Reading 185
 Frequently Asked Questions 185
 Multiple Choice Questions 185
 Viva Voce 186

13. Arches of Foot

187

Introduction 187
 Formation or Structure of Arches 187
 Medial Longitudinal Arch 187
 Lateral Longitudinal Arch 188
 Anterior Transverse Arch 188
 Posterior Transverse Arch 188
 Factors Responsible for Maintenance of Arches 188
 Functions of Arches 190
 Summary 190
 Comparison of Medial and Lateral Longitudinal Arches 190
 Clinical Anatomy 191
 Facts to Remember 192
 Clinicoanatomical Problem 192
 Frequently Asked Questions 193
 Multiple Choice Questions 193
 Viva Voce 193

14. Surface and Radiological Anatomy

194

Palpable Parts of the Bones 194
 Surface Marking 195
 Arteries 195
 Femoral Artery 195
 Profunda Femoris Artery 195
 Popliteal Artery 195
 Superior Gluteal Artery 195
 Inferior Gluteal Artery 195
 Anterior Tibial Artery 196
 Posterior Tibial Artery 196
 Dorsalis Pedis Artery 196
 Medial Plantar Artery 197
 Lateral Plantar Artery 197
 Plantar Arch 197
 Veins 197
 Femoral Vein 197
 Great Saphenous Vein 197
 Small Saphenous Vein 198
 Nerves 198
 Femoral Nerve 198
 Sciatic Nerve 198
 Tibial Nerve 198
 Common Peroneal Nerve 198
 Deep Peroneal Nerve 199
 Superficial Peroneal Nerve 199
 Medial Plantar Nerve 199
 Lateral Plantar Nerve 199
 Miscellaneous Structures 199
 Saphenous Opening 199
 Femoral Ring 199
 Superior Extensor Retinaculum 199
 Inferior Extensor Retinaculum 199
 Flexor Retinaculum 200
 Radiological Anatomy 200
 Hip 200
 Knee 201
 Foot 201
 Further Reading 202

Appendix 1: Nerves, Arteries and Clinical Terms

203

Nerves of Lower Limb 203
 Femoral Nerve 203
 Obturator Nerve 203
 Accessory Obturator Nerve 204
 Superior Gluteal Nerve 204
 Inferior Gluteal Nerve 204
 Nerve to Quadratus Femoris 204
 Nerve to Obturator Internus 205
 Sciatic Nerve 205

Tibial Nerve 206
 Common Peroneal Nerve 206
 Deep Peroneal Nerve 206
 Superficial Peroneal Nerve 207
 Plantar Nerves 208
 Arteries of Lower Limb 210
 Clinical Anatomy 211
 Clinical Terms 212
 Multiple Choice Questions 213
 Early Clinical Exposure (ECE) Cases 214
 Spots on Lower Limb 215
 Answers: Spots on Lower Limb 216

Section 2 ABDOMEN AND PELVIS**15. Introduction and Osteology**

219

Introduction to Abdomen 219
 Osteology 219
 Lumbar Vertebrae 219
 Ossification 222
 Clinical Anatomy 222
 The Sacrum/Vertebra Magnum 224
 Sacral Canal 226
 Attachments on the Sacrum 226
 Relations of the Sacrum 226
 Sex Differences 227
 Ossification 227
 Coccyx 227
 Ossification 228
 Bony Pelvis 228
 Sex Differences in the Pelvis 229
 Anatomical Position of the Pelvis 229
 Intervertebral Joints 230
 Intervertebral Disc 230
 Video 2.15.1 Lumbar Vertebrae
 Video 2.15.2 Sacrum and Coccyx
 Video 2.15.3 Bony Pelvis
 Video 2.15.4 Pelvic Cavity
 Mnemonics 231
 Facts to Remember 231
 Clinicoanatomical Problem 231
 Further Reading 231
 Frequently Asked Questions 232
 Multiple Choice Questions 232
 Viva Voce 232

16. Anterior Abdominal Wall

233

Surface Landmarks 233
 Skin and Superficial Fascia 234
 Dissection 234
 Umbilicus 235
 Clinical Anatomy 236
 Superficial Fascia 237
 Clinical Anatomy 237
 Cutaneous Nerves 237
 Cutaneous Arteries 238
 Cutaneous Veins 238
 Clinical Anatomy 239
 Muscles of the Anterolateral Abdominal Wall 239
 External Oblique Muscle 239
 Internal Oblique Muscle 240

Dissection 240
 Transversus Abdominis Muscle 241
 Dissection 241
 Rectus Abdominis Muscle 241
 Actions of the Main Muscles of the Anterior Abdominal Wall 242
 Inguinal Ligament 242
 Conjoint Tendon or Falx Inguinalis 243
 Cremaster Muscle 243
 Pyramidalis 243
 Dissection 243
 Clinical Anatomy 244
 Deep Nerves 244
 Deep Arteries 244
 Rectus Sheath 246
 New Concepts of Rectus Sheath 247
 Fascia Transversalis 248
 Dissection 248
 Inguinal Canal 249
 Definition 249
 Boundaries 249
 Structures Passing through Inguinal Canal 250
 Constituents of the Spermatic Cord 250
 Mechanism of Inguinal Canal 251
 Development of Inguinal Canal 251
 Dissection 251
 Clinical Anatomy 251
 Video 2.16 Anterior Abdominal Wall
 Mnemonics 254
 Facts to Remember 254
 Clinicoanatomical Problem 254
 Further Reading 255
 Frequently Asked Questions 255
 Multiple Choice Questions 255
 Viva Voce 256

17. Male External Genital Organs

257

Introduction 257
 Dissection 257
 External Genital Organs 257
 Penis 257
 Root of Penis 257
 Body of Penis and its Histology 258
 Clinical Anatomy 260
 Scrotum 260
 Clinical Anatomy 261
 Testis 261
 External Features 262

Arterial Supply 263
 Histology of Seminiferous Tubule 264
Clinical Anatomy 264
 Epididymis 265
Clinical Anatomy 265
 Histology 265
 Development of Male Reproductive System 266
 Descent of the Testis 266
 Ducts 266
 External Genitalia 267
 Molecular Regulation 267
Facts to Remember 267
Clinicoanatomical Problem 267
 Further Reading 268
Frequently Asked Questions 268
Multiple Choice Questions 268
Viva Voce 269

18. Abdominal Cavity and Peritoneum 270

Introduction 270
 Nine Regions of Abdomen 270
 Peritoneum 271
 Functions of Peritoneum 272
Clinical Anatomy 273
 Peritoneal Folds 273
 Greater Omentum 274
Dissection 275
 Lesser Omentum 276
 Mesentery 277
 Mesoappendix 277
Dissection 277
 Transverse Mesocolon 278
Dissection 278
 Sigmoid Mesocolon 278
Dissection 278
 Reflection of Peritoneum 278
 Peritoneal Cavity 279
 Vertical Tracing/Sagittal Tracing 279
 Horizontal Tracing above Transverse Colon 280
 Horizontal Tracing below the Level of the Transverse Colon 280
 Horizontal Tracing of Peritoneum in the Lesser Pelvis/True Pelvis (Male) 281
 Horizontal Tracing of Peritoneum in the Lesser Pelvis/True Pelvis (Female) 281
 Epiploic Foramen/Omental Foramen/Foramen of Winslow 281
 Lesser Sac or Omental Bursa 282
Clinical Anatomy 283
 Special Regions of the Peritoneal Cavity 283
 Supracolic Compartment/Subphrenic Spaces 284
 Hepatorenal Pouch (Morrison's Pouch) 285
 Infracolic Compartments 285
 Paracolic Gutters 285
 Rectouterine Pouch (Pouch of Douglas) 285
Clinical Anatomy 285
 Peritoneal Fossae (Recesses) 286
Clinical Anatomy 287
 Development of Gut and its Folds 288
Video 2.18 Peritoneal Cavity
Facts to Remember 288
Clinicoanatomical Problem 288
 Further Reading 289
Frequently Asked Questions 289
Multiple Choice Questions 289
Viva Voce 290

19. Abdominal Part of Oesophagus and Stomach 291

Introduction 291
Dissection 291
 Abdominal Part of Oesophagus 291
 Histology 292
Clinical Anatomy 292
 Stomach 294
 Location 294
 External Features 294
 Relations of Stomach 295
 Blood Supply 296
 Lymphatic Drainage 296
 Nerve Supply 297
 Interior of Stomach 297
 Functions of Stomach 297
Dissection 298
Clinical Anatomy 298
 Histology of Stomach 299
 Development 299
 Molecular Regulation of Gut Tube Development 299
Video 2.19 Stomach
 Mnemonics 300
Facts to Remember 300
Clinicoanatomical Problem 300
 Further Reading 300
Frequently Asked Questions 301
Multiple Choice Questions 301
Viva Voce 301

20. Small and Large Intestines 302

Introduction 302
 Small Intestine 302
 Relevant Features 302
 Large Surface Area 302
 Duodenum 304
Dissection 304
 Peritoneal Relations 305
 Suspensory Muscle of Duodenum or Ligament of Treitz 307
 Histology 308
Clinical Anatomy 308
 Jejunum and Ileum 309
 Histology 310
 Meckel's Diverticulum (Diverticulum Ile) 310
Dissection 310
Clinical Anatomy 310
 Large Intestine 311
Dissection 313
Clinical Anatomy 313
 Caecum 313
Dissection 314
Clinical Anatomy 315
 Vermiform Appendix 315
 Histology 317
Clinical Anatomy 317
 Ascending Colon 318
 Right Colic Flexure (Hepatic Flexure) 318
 Transverse Colon 318
 Left Colic Flexure (Splenic Flexure) 318
 Descending Colon 318
 Sigmoid Colon (Pelvic Colon) 318
 Histology of Colon 319
 Development of Intestines 319

► **Video 2.20 Small and Large Intestines**

Mnemonics 320
 Facts to Remember 320
 Clinicoanatomical Problem 320
 Further Reading 320
 Frequently Asked Questions 321
 Multiple Choice Questions 321
 Viva Voce 322

21. Large Blood Vessels of the Gut 323

Introduction 323
 Blood Vessels 323
 Coeliac Trunk 323
 Origin and Length 323
 Branches 324
 Superior Mesenteric Artery 325
 Origin, Course and Termination 325
 Branches 326
 Superior Mesenteric Vein 327
 Dissection 328
 Clinical Anatomy 328
 Inferior Mesenteric Artery 328
 Branches 328
 Inferior Mesenteric Vein 328
 Clinical Anatomy 329
 Marginal Artery of Drummond 329
 Portal Vein 329
 Branches 331
 Tributaries 331
 Portosystemic Communications
 (Portocaval Anastomoses) 331
 Clinical Anatomy 332
 Development 333
 Facts to Remember 333
 Clinicoanatomical Problem 333
 Further Reading 334
 Frequently Asked Questions 334
 Multiple Choice Questions 334
 Viva Voce 335

22. Extrahepatic Biliary Apparatus 336

Introduction 336
 Right and Left Hepatic Ducts 336
 Common Hepatic Duct 336
 Gallbladder 336
 Cystic Duct 338
 Bile Duct 338
 Sphincters Related to the Bile and Pancreatic Ducts 339
 Vascular and Nerve Supply 339
 Dissection 340
 Clinical Anatomy 340
 Histology of Gallbladder 341
 Development 342
 Facts to Remember 342
 Clinicoanatomical Problems 342
 Further Reading 342
 Frequently Asked Questions 343
 Multiple Choice Questions 343
 Viva Voce 343

23. Spleen, Pancreas and Liver 344

Introduction 344
 Spleen 344
 Dissection 344

External Features 345
 Relations 345
 Arterial Supply 346
 Venous Drainage 347
 Lymphatic Drainage 347
 Clinical Anatomy 347
 Histology 349
 Development 349
 Pancreas 349
 Head of the Pancreas 349
 Body of the Pancreas 350
 Tail of the Pancreas 351
 Ducts of the Pancreas 351
 Arterial Supply 352
 Venous Drainage 352
 Lymphatic Drainage 352
 Nerve Supply 352
 Functions 353
 Dissection 353
 Clinical Anatomy 353
 Histology 353
 Development 354
 Molecular Regulation 355
 Liver 355
 External Features 355
 Relations 356
 Arterial Supply 357
 Venous Drainage 358
 Lymphatic Drainage 358
 Nerve Supply 358
 Hepatic Segments 358
 Dissection 359
 Clinical Anatomy 359
 Histology 360
 Development 361
 Molecular Regulation 361
 ► **Video 2.23 Glands of Abdominal Cavity**
 Mnemonics 361
 Facts to Remember 361
 Clinicoanatomical Problem 362
 Further Reading 362
 Frequently Asked Questions 362
 Multiple Choice Questions 363
 Viva Voce 363

24. Kidney and Ureter 364

Kidney 364
 External Features 365
 Hilum 365
 Relations of the Kidneys 365
 Capsules or Coverings of Kidney 365
 Structure 367
 Blood Supply of Kidney 369
 Lymphatic Drainage 369
 Nerve Supply 369
 Exposure of the Kidney from Behind 369
 Histology 370
 Dissection 371
 Clinical Anatomy 371
 Ureter 373
 Dimensions 373
 Normal Constrictions 374
 Relations 374
 Abdominal Part of Ureter 374
 Pelvic Part of Ureter 375

Intravesical Part 376
 Blood Supply 376
 Nerve Supply 376
 Histology 376
Clinical Anatomy 377
 Development of Kidney and Ureter 377
 Anomalies of the Kidney and Ureter 377
 Molecular Regulation of Kidney Development 377
 • **Video 2.24 Kidney and Ureter**
 Mnemonics 377
Facts to Remember 379
Clinicoanatomical Problem 379
 Further Reading 379
Frequently Asked Questions 379
Multiple Choice Questions 380
Viva Voce 380

25. Suprarenal Gland and Chromaffin System

381

Suprarenal Gland 381
 Right Suprarenal Gland 381
 Left Suprarenal Gland 382
 Structure and Function 382
 Arterial Supply 383
 Venous Drainage 383
 Lymphatic Drainage 383
 Nerve Supply 383
Clinical Anatomy 383
 Histology 384
 Development 384
 Molecular Regulation 384
Dissection 384
 Chromaffin System 384
Facts to Remember 385
Clinicoanatomical Problem 385
 Further Reading 385
Frequently Asked Questions 386
Multiple Choice Questions 386
Viva Voce 386

26. Thoracoabdominal Diaphragm

387

Introduction 387
 Gross Anatomy 387
 Openings in the Thoracoabdominal Diaphragm 389
 Relations 389
 Nerve Supply 389
 Actions 390
Dissection 390
Clinical Anatomy 390
 Development 391
 Mnemonics 391
Facts to Remember 392
Clinicoanatomical Problem 392
 Further Reading 392
Frequently Asked Questions 393
Multiple Choice Questions 393
Viva Voce 393

27. Posterior Abdominal Wall

394

Introduction 394
 Blood Vessels, Muscles and Nerves 394
 Abdominal Aorta 394
 Relations 394

Branches 394
 Common Iliac Arteries 396
 Inferior Vena Cava 396
 Tributaries 396
Clinical Anatomy 397
 Abdominal Parts of Azygos and Hemiazygos Veins 397
 Lymph Nodes of Posterior Abdominal Wall 398
 Cisterna Chyli 398
 Muscles of the Posterior Abdominal Wall 398
Dissection 398
Clinical Anatomy 400
 Thoracolumbar Fascia (Lumbar Fascia) 400
 Nerves of the Posterior Abdominal Wall 401
 Abdominal Part of the Autonomic Nervous System 402
 Lumbar Sympathetic Chain 402
 Coeliac Ganglia and Coeliac Plexus 402
 Superior Hypogastric Plexus (Presacral Nerve) 403
 Inferior Hypogastric Plexuses 404
Clinical Anatomy 404
 Layers of the Abdomen 405
 Mnemonics 406
Facts to Remember 406
Clinicoanatomical Problem 406
 Further Reading 406
Frequently Asked Questions 407
Multiple Choice Questions 407
Viva Voce 407

28. Perineum

408

Introduction 408
 Superficial Boundaries 408
 Deep Boundaries of the Perineum 408
 Divisions of the Perineum 409
 Anal Region 409
 Perineal Body 409
 External Anal Sphincter 410
 Ischioanal Fossa 410
 Spaces and Canals of the Fossa 411
 Contents of Ischioanal Fossa 411
Dissection 412
Clinical Anatomy 412
 Male Perineum 412
 Male External Genital Organs 412
 Male Urogenital Region 412
Dissection 413
Clinical Anatomy 413
 Superficial Perineal Space 413
 Deep Perineal Space 413
 Boundaries 416
 Deep Transversus Perinei 416
 Distal Urethral Sphincter Mechanism 416
 Perineal Membrane 416
Clinical Anatomy 417
 Female Perineum 418
 Female External Genital Organs/Pudendum/Vulva 418
 Female Urogenital Region 419
Clinical Anatomy 419
 Superficial Perineal Space 420
 Deep Perineal Space 420
 Boundaries 420
 Contents 420
 Urethral Sphincter Mechanism 420
 Compressor Urethrae 420
 Sphincter Urethrovaginalis 420
 Perineal Membrane 421

Pudendal Canal 421
 Pudendal Nerve 422
Clinical Anatomy 423
 Internal Pudendal Artery 423
 Internal Pudendal Vein 424
 Histology of Body of Penis/Clitoris 424
Facts to Remember 424
Clinicoanatomical Problem 425
 Further Reading 425
Frequently Asked Questions 425
Multiple Choice Questions 425
Viva Voce 426

29. Preliminary Consideration of Boundaries and Contents of Pelvis 427

Introduction 427
 Lesser Pelvis 427
 Muscles 427
 Pelvic Inlet (Superior Aperture of Pelvis) 428
 Pelvic Outlet (Inferior Aperture of Pelvis) 429
Clinical Anatomy 429
 Pelvic Floor 429
Clinical Anatomy 429
 Pelvic Cavity 430
 Contents 430
 Structures Crossing the Pelvic Inlet/Brim of the Pelvis 430
Facts to Remember 431
Clinicoanatomical Problem 431
 Further Reading 431
Frequently Asked Questions 432
Multiple Choice Questions 432
Viva Voce 432

30. Urinary Bladder and Urethra 433

Introduction 433
 Urinary Bladder 433
 External Features 433
 Relations 434
 Ligaments of the Bladder 434
 Interior of the Bladder 435
 Arterial Supply 435
 Venous Drainage 435
 Lymphatic Drainage 436
 Nerve Supply 436
 Histology of Urinary Bladder 436
Dissection 436
Clinical Anatomy 436
 Urethra 437
 Male Urethra 437
 Posterior Part 438
 Anterior Part 439
Clinical Anatomy 440
 Female Urethra 440
 Walls of Urethra 440
 Micturition 441
Clinical Anatomy 441
 Development of Urinary Bladder and Urethra 441
Facts to Remember 442
Clinicoanatomical Problem 442
 Further Reading 442
Frequently Asked Questions 443
Multiple Choice Questions 443
Viva Voce 443

31. Female Reproductive Organs 444

Introduction 444
 Internal Genital Organs 444
 Ovaries 444
 External Features 445
 Relations 445
 Arterial Supply 446
 Venous Drainage 446
 Histology 446
Clinical Anatomy 447
Dissection 447
 Uterine Tubes 447
 Course and Relations 447
 Blood Supply 448
 Lymphatic Drainage 448
 Nerve Supply 448
 Histology 448
Clinical Anatomy 449
 Uterus 449
 Size and Shape 450
 Normal Position and Angulation 450
 Parts of Uterus 451
 Cervix of Uterus 451
 Ligaments of Uterus 452
 Arterial Supply 452
 Venous Drainage 453
 Lymphatic Drainage 453
 Nerve Supply 453
 Age and Reproductive Changes 453
 Supports of the Uterus 453
 Role of Individual Supports 454
 Histology 455
Clinical Anatomy 456
 Vagina 456
 Extent and Situation 457
 Fornices of Vagina 457
 Relations 457
 Arterial Supply 457
 Venous Drainage 458
 Lymphatic Drainage 458
 Nerve Supply 458
 Ureter in Female Pelvis 458
 Histology 458
Clinical Anatomy 459
 Development 459
 Molecular Regulation 461
▶ Video 2.31 Female Reproductive System
 Mnemonics 461
Facts to Remember 461
Clinicoanatomical Problem 461
 Further Reading 462
Frequently Asked Questions 462
Multiple Choice Questions 462
Viva Voce 463

32. Male Internal Genital Organs 464

Introduction 464
Dissection 464
 Ductus Deferens 464
 Course and Relations 464
 Arterial Supply 465
 Venous Drainage 465
 Histology 466
 Development 466

- Clinical Anatomy 466
- Seminal Vesicles 466
- Ejaculatory Duct 466
- Prostate 466
- Situation 467
- Gross Features 467
- Zones of the Prostate 467
- Capsules and Ligaments of Prostate 468
- Structures within the Prostate 468
- Structural Zones of the Prostate 469
- Blood Supply 469
- Lymphatic Drainage 469
- Nerve Supply 469
- Age Changes in Prostate 469
- Histology 470
- Development 470
- Clinical Anatomy 470
- Vertebral System of Veins/Batson's Plexus 471
- Communications and Implications 471
- Video 2.32 Male Reproductive System
- Facts to Remember 471
- Clinicoanatomical Problems 471
- Further Reading 472
- Frequently Asked Questions 472
- Multiple Choice Questions 472
- Viva Voce 473

33. Rectum and Anal Canal

474

- Introduction 474
- Rectum 474
- Situation 474
- Dimensions 474
- Relations 475
- Mucosal Folds 475
- Arterial Supply 476
- Venous Drainage 477
- Lymphatic Drainage 477
- Nerve Supply 478
- Supports of Rectum 478
- Dissection 478
- Clinical Anatomy 479
- Anal Canal 480
- Length, Extent and Direction 480
- Relations of the Anal Canal 480
- Interior of the Anal Canal 480
- Musculature of the Anal Canal 481
- Anorectal Ring 481
- Surgical Spaces Related to the Anal Canal 482
- Arterial Supply 482
- Venous Drainage 482
- Lymphatic Drainage 482
- Nerve Supply 483
- Dissection 483
- Clinical Anatomy 483
- Histology 484
- Development 484
- Facts to Remember 484
- Clinicoanatomical Problem 485
- Further Reading 485
- Frequently Asked Questions 485
- Multiple Choice Questions 485
- Viva Voce 486

34. Walls of Pelvis

487

- Introduction 487
- Vessels of the Pelvis 487
- Internal Iliac Artery 487
- Course 487
- Relations 487
- Branches 487
- Branches of Anterior Division 487
- Branches of Posterior Division 489
- Internal Iliac Vein 489
- Lymph Nodes of the Pelvis 490
- Dissection 490
- Nerves of the Pelvis 490
- Lumbosacral Plexus 490
- Branches from Dorsal Divisions 490
- Branches from Ventral Division 491
- Coccygeal Plexus 491
- Clinical Anatomy 491
- Pelvic Autonomic Nerves 491
- Pelvic Sympathetic System 491
- Pelvic Splanchnic Nerves 491
- Dissection 491
- Pelvic Fascia 492
- Pelvic Muscles 492
- Levator Ani 493
- Pubococcygeus Part 493
- Iliococcygeus Part 493
- Ischiococcygeus Part 494
- Nerve Supply 494
- Actions of the Levator Ani and Coccygeus 494
- Relations of the Levator Ani 494
- Dissection 494
- Clinical Anatomy 494
- Joints of Pelvis 495
- Lumbosacral Joints 495
- Sacrococcygeal and Intercoccygeal Joints 495
- Sacroiliac Joint 495
- Ligaments 496
- Factors Providing Stability 497
- Blood Supply 497
- Nerve Supply 497
- Movements 497
- Pubic Symphysis 497
- Mechanism of Pelvis 497
- Dissection 497
- Clinical Anatomy 498
- Facts to Remember 498
- Clinicoanatomical Problem 498
- Further Reading 498
- Frequently Asked Questions 499
- Multiple Choice Questions 499
- Viva Voce 499

35. Surface Marking of Abdomen and Pelvis

500

- Planes and Regions of the Abdomen 500
- Surface Marking 500
- Viscera 500
- Spleen 500
- Stomach 500
- Duodenum 501
- Caecum 501
- Ileocaecal Orifice or Valve 501

Appendix 501
 Ascending Colon 501
 Transverse Colon 502
 Descending Colon 502
 Rectum and Anal Canal 502
 Liver 502
 Gallbladder 502
 Bile Duct 502
 Pancreas 502
 Kidney 502
 Ureter 503
 Vessels 503
 Abdominal Aorta 503
 Common Iliac Artery 503
 External Iliac Artery 503
 Coeliac Trunk and its Branches 503
 Superior Mesenteric Artery 503
 Inferior Mesenteric Artery 504
 Inferior Vena Cava 504
 Portal Vein 504
 Miscellaneous 504
 Inguinal Canal 504
 Root of Mesentery 504
 Further Reading 504

36. Radiological and Imaging Procedures 505

Introduction 505
 Plain Skiagram of Abdomen 505
 Alimentary Canal (Barium Studies) 506
 Barium Meal Examination 506
 Barium Enema 507
 Pyelography 507
 Excretory (Intravenous or Descending) Pyelography 507

Retrograde (Instrumental or Ascending) Pyelography 508
 Biliary Apparatus (Ultrasonography) 508
 Hysterosalpingography 509
 Further Reading 509

Appendix 2: Nerves, Arteries and Clinical Terms

510

Nerves of Abdomen 510
 Lower Intercostal Nerves 510
 Upper Lumbar Nerves 510
 Lumbar Plexus 510
 Sacral Plexus 511
 Pudendal Nerve 511
 Abdominal Part of Sympathetic Trunk 511
 Aortic Plexus 511
 Pelvic Part of Sympathetic Trunk 511
 Collateral or Prevertebral Ganglia and Plexuses 512
 Coeliac Plexus 512
 Superior Hypogastric Plexus 512
 Autonomic Nerve Supply of Various Organs 512
 Gastrointestinal Tract 512
 Genitourinary Tract 513
 Clinical Anatomy 514
 Arteries of Abdomen and Pelvis 514
 Clinical Terms 517
 Multiple Choice Questions 520
 Early Clinical Exposure (ECE) Cases 521
 Spots on Abdomen and Pelvis 523
 Answers: Spots on Abdomen and Pelvis 524

Index

525



Ethical Aspects of Cadaveric Dissection

The cadaver, the dead body, that we dissect, plays an important role in the teaching of anatomy to medical students. The cadaver and the bones become an important part of our life as medical students as some academics have even referred to the cadaver as the 'first teacher' in the medical school.

We must pay due respect to the cadavers and bones kept in the dissection hall or museum. In some medical schools, it is mandatory to take an 'oath' before beginning the cadaveric dissection which aims to uphold the dignity of the mortal remains of the departed soul while other medical schools help the student to undertake dissection in a proper manner and empathise with the families of the donor. During the course of dissection, the student is constantly reminded of the sanctity of the body he/she is studying so that the noble donation of someone's body is used only as a means of gaining scientific knowledge/progress. Each and every dissected part afterwards is disposed or cremated with full dignity.

Honour of the donor and his/her family is the prime responsibility of the health professional. 'The dead teach the living', and the living pledge to use this knowledge for the upliftment of humankind.

Three-dimensional models and computer simulations cannot replace the tactile appreciation achieved by cadaveric dissection and we should always be grateful to those who have donated their bodies and strive to respect them. We have the privilege to study the human being through a body of a fellow human and have to be humble and carry forward the legacy of nobility and selflessness in our careers.

(Contributed by Dr Puneet Kaur)

Index of Competencies



Competency based Undergraduate Curriculum for the Indian Medical Graduate

Code	Competency	Chapter	Page no
AN 14.1	Identify the given bone, its side, important features and keep it in anatomical position	2	7
AN 14.2	Identify and describe joints formed by the given bone	2	7
AN 14.3	Describe the importance of ossification of lower end of femur and upper end of tibia	2	21
AN 14.4	Identify and name various bones in the articulated foot with individual muscle attachment	2	32
AN 15.1	Describe and demonstrate origin, course, relations, branches (or tributaries), termination of important nerves and vessels of anterior thigh	3, 4	57, 69
AN 15.2	Describe and demonstrate major muscles with their attachment, nerve supply and actions	3, 4	60, 67
AN 15.3	Describe and demonstrate boundaries, floor, roof and contents of femoral triangle	3	52
AN 15.4	Explain anatomical basis of psoas abscess and femoral hernia	3	55, 61
AN 15.5	Describe and demonstrate adductor canal with its content	3	63
AN 16.1	Describe and demonstrate origin, course, relations, branches (or tributaries), termination of important nerves and vessels of gluteal region	5	82
AN 16.2	Describe anatomical basis of sciatic nerve injury during gluteal intramuscular injections	5	80
AN 16.3	Explain the anatomical basis of Trendelenburg sign	5	82
AN 16.4	Describe and demonstrate the hamstrings group of muscles with their attachment, nerve supply and actions	7	95
AN 16.5	Describe and demonstrate the origin, course, relations, branches (or tributaries), termination of important nerves and vessels on the back of thigh	7	99
AN 16.6	Describe and demonstrate the boundaries, roof, floor, contents and relations of popliteal fossa	6	87
AN 17.1	Describe and demonstrate the type, articular surfaces, capsule, synovial membrane, ligaments, relations, movements and muscles involved, blood and nerve supply, bursae around the hip joint	12	161
AN 17.2	Describe anatomical basis of complications of fracture neck of femur	12	164
AN 17.3	Describe dislocation of hip joint and surgical hip replacement	12	164
AN 18.1	Describe and demonstrate major muscles of anterior compartment of leg with their attachment, nerve supply and actions	8	109
AN 18.2	Describe and demonstrate origin, course, relations, branches (or tributaries), termination of important nerves and vessels of anterior compartment of leg	8	109
AN 18.3	Explain the anatomical basis of foot drop	8	115
AN 18.4	Describe and demonstrate the type, articular surfaces, capsule, synovial membrane, ligaments, relations, movements and muscles involved, blood and nerve supply, bursae around the knee joint	12	166
AN 18.5	Explain the anatomical basis of locking and unlocking of the knee joint	12	171
AN 18.6	Describe knee joint injuries with its applied anatomy	12	173
AN 18.7	Explain anatomical basis of osteoarthritis	12	173
AN 19.1	Describe and demonstrate the major muscles of back of leg with their attachment, nerve supply and actions	9	126
AN 19.2	Describe and demonstrate the origin, course, relations, branches (or tributaries), termination of important nerves and vessels of back of leg	9	130
AN 19.3	Explain the concept of "Peripheral heart"	9	127
AN 19.5	Describe factors maintaining importance arches of the foot with its importance	13	187

<i>Code</i>	<i>Competency</i>	<i>Chapter</i>	<i>Page no</i>
AN 19.6	Explain the anatomical basis of flat foot and club foot	13	191
AN 19.7	Explain the anatomical basis of metatarsalgia and plantar fasciitis	10	137
AN 20.1	Describe and demonstrate the type, articular surfaces, capsule, synovial membrane, ligaments, relations, movements and muscles involved, blood and nerve supply of tibiofibular and ankle joint	12	174
AN 20.2	Describe the subtalar and transverse tarsal joints	12	179
AN 20.3	Describe and demonstrate fascia lata, venous drainage, lymphatic drainage, retinacula and dermatomes of lower limb	11	148
AN 20.4	Explain anatomical basis of enlarged inguinal lymph nodes	11	154
AN 20.5	Explain anatomical basis of varicose veins and deep vein thrombosis	11	151
AN 20.6	Identify the bones and joints of lower limb seen in anteroposterior and lateral view radiographs of various regions of lower limb	14	200
AN 20.7	Identify and demonstrate important bony landmarks of lower limb: Vertebral levels of highest point of iliac crest, posterior superior iliac spines, iliac tubercle, pubic tubercle, ischial tuberosity, adductor tubercle, tibial tuberosity, head of fibula, medial and lateral malleoli, condyles of femur and tibia, sustentaculum tali, tuberosity of fifth metatarsal, tuberosity of the navicular	14	194
AN 20.8	Identify and demonstrate palpation of femoral, popliteal, posterior tibial, anterior tibial and dorsalis pedis blood vessels in a simulated environment	14	195
AN 20.9	Identify and demonstrate Palpation of vessels (femoral, popliteal, dorsalis pedis, post-tibial), mid-inguinal point, Surface projection of: Femoral nerve, saphenous opening, Sciatic, tibial, common peroneal and deep peroneal nerve, Great and small saphenous veins	14	198
AN 20.10	Describe basic concept of development of lower limb	1	3
AN 44.1	Describe and demonstrate the planes (transpyloric, transtubercular, subcostal, lateral vertical, linea alba, linea semilunaris), regions and quadrants of abdomen	18	270
AN 44.2	Describe and identify the fascia, nerves and blood vessels of anterior abdominal wall	16	237
AN 44.3	Describe the formation of rectus sheath and its contents	16	246
AN 44.4	Describe and demonstrate extent, boundaries, contents of Inguinal canal including Hesselbach's triangle	16	249
AN 44.5	Explain the anatomical basis of inguinal hernia	16	251
AN 44.6	Describe and demonstrate attachments of muscles of anterior abdominal wall	16	239
AN 44.7	Enumerate common abdominal incisions	16	244
AN 45.1	Describe thoracolumbar fascia	27	400
AN 45.2	Describe and demonstrate Lumbar plexus for its root value, formation and branches	27	401
AN 45.3	Mention the major subgroups of back muscles, nerve supply and action	27	398
AN 46.1	Describe and demonstrate coverings, internal structure, side determination, blood supply, nerve supply, lymphatic drainage and descent of testis with its applied anatomy	17	261
AN 46.2	Describe parts of epididymis	17	265
AN 46.3	Describe penis under following headings: Parts, components, blood supply and lymphatic drainage	17	257
AN 46.4	Explain the anatomical basis of varicocele	17	264
AN 46.5	Explain the anatomical basis of Phimosi and circumcision	17	260
AN 47.1	Describe and identify boundaries and recesses of lesser and greater sac	18	279, 282
AN 47.2	Name and identify various peritoneal folds and pouches with its explanation	18	283
AN 47.3	Explain anatomical basis of ascites and peritonitis	18	273, 285
AN 47.4	Explain anatomical basis of subphrenic abscess	18	285
AN 47.5	Describe and demonstrate major viscera of abdomen under following headings: anatomical position, external and internal features, important peritoneal and other relations, blood supply, nerve supply, lymphatic drainage and applied aspects)	19 20	291 302

<i>Code</i>	<i>Competency</i>	<i>Chapter</i>	<i>Page no</i>
AN 47.6	Explain the anatomical basis of splenic notch, accessory spleens, Kehr's sign, different types of vagotomy, liver biopsy (site of needle puncture), referred pain in cholecystitis, obstructive jaundice, referred pain around umbilicus, radiating pain of kidney to groin and lymphatic spread in carcinoma stomach	22, 23	340, 347, 359
AN 47.7	Mention the clinical importance of Calot's triangle	22	340
AN 47.8	Describe and identify the formation, course relations and tributaries of portal vein, inferior vena cava and renal vein	21, 27	329, 396, 397
AN 47.9	Describe and identify the origin, course, important relations and branches of abdominal aorta, coeliac trunk, superior mesenteric, inferior mesenteric and common iliac artery	21, 27	323, 394, 396
AN 47.10	Enumerate the sites of portosystemic anastomosis	21	331
AN 47.11	Explain the anatomic basis of hematemesis and caput medusae in portal hypertension	21	331
AN 47.12	Describe important nerve plexuses of posterior abdominal wall	27	402
AN 47.13	Describe and demonstrate the attachments, openings, nerve supply and action of the thoracoabdominal diaphragm	26	387
AN 47.14	Describe the abnormal openings of thoracoabdominal diaphragm and diaphragmatic hernia	26	390
AN 48.1	Describe and identify the muscles of Pelvic diaphragm	34	492
AN 48.2	Describe and demonstrate the (position, features, important peritoneal and other relations, blood supply, nerve supply, lymphatic drainage and clinical aspects of) important male and female pelvic viscera	31, 32	444, 464
AN 48.3	Describe and demonstrate the origin, course, important relations and branches of internal iliac artery	34	487
AN 48.4	Describe the branches of sacral plexus	34	490
AN 48.5	Explain the anatomical basis of suprapubic cystostomy, urinary obstruction in benign prostatic hypertrophy, retroverted uterus, prolapse uterus, internal and external haemorrhoids, anal fistula, vasectomy, tubal pregnancy and tubal ligation	31, 32	449, 456, 466
AN 48.6	Describe the neurological basis of automatic bladder	30	436
AN 48.7	Mention the lobes involved in benign prostatic hypertrophy and prostatic cancer	32	470
AN 48.8	Mention the structures palpable during vaginal and rectal examination	31, 33	456, 479
AN 49.1	Describe and demonstrate the superficial and deep perineal pouch (boundaries and contents)	28	415
AN 49.2	Describe and identify perineal body	28	409
AN 49.3	Describe and demonstrate perineal membrane in male and female	28	415
AN 49.4	Describe and demonstrate boundaries, content and applied anatomy of Ischiorectal fossa	28	410
AN 49.5	Explain the anatomical basis of perineal tear, episiotomy, perianal abscess and anal fissure	28, 33	412, 483
AN 50.2	Describe and demonstrate the type, articular ends, ligaments and movements of intervertebral joints, sacroiliac joints and pubic symphysis	34	495
AN 50.4	Explain the anatomical basis of scoliosis, lordosis, prolapsed disc, spondylolisthesis and spina bifida	15	222
AN 52.1	Describe and identify the microanatomical features of gastro-intestinal system: Oesophagus, fundus of stomach, pylorus of stomach, duodenum, jejunum, Ileum, large intestine, appendix, liver, gall bladder, pancreas and suprarenal gland, colon	19, 20 22, 23 25, 33	299, 308, 309, 317, 319, 341, 349, 353, 360, 384, 484
AN 52.2	Describe and identify the microanatomical features of: Urinary system: Kidney, ureter and urinary bladder male reproductive system: Testis, epididymis, vas deferens, prostate and penis female reproductive system: Ovary, uterus, uterine tube, cervix, placenta and umbilical cord	17, 24, 30, 31, 32	258, 264, 265, 370, 376, 436, 446, 448, 455, 458, 465, 470
AN 52.5	Describe the development and congenital anomalies of Diaphragm	26	390, 391
AN 52.6	Describe the development and congenital anomalies of: Foregut, midgut and hindgut, caecum, spleen, pancreas, liver, gallbladder	19, 20 22, 23 33	299, 313, 319 342, 349, 354 361, 484
AN 52.7	Describe the development of urinary system	24, 25	377, 384

<i>Code</i>	<i>Competency</i>	<i>Chapter</i>	<i>Page no</i>
AN 52.8	Describe the development of male and female reproductive system	17, 31, 32	265, 459, 466
AN 53.2	Demonstrate the anatomical position of bony pelvis and show boundaries of pelvic inlet, pelvic cavity, pelvic outlet	29	427
AN 53.3	Define true pelvis and false pelvis and demonstrate sex determination in male and female bony pelvis	15	229
AN 53.4	Explain and demonstrate clinical importance of bones of abdominopelvic region (sacralization of lumbar vertebra, lumbarization of 1st sacral vertebra, types of bony pelvis and coccyx)	15	222
AN 54.1	Describe and identify features of plain X-ray abdomen	36	505
AN 54.2	Describe and identify the special radiographs of abdominopelvic region (contrast X-ray barium swallow, barium meal, barium enema, cholecystography, intravenous pyelography and hysterosalpingography)	36	506